

## CHAPTER 68

# Upper eyelid rejuvenation

Adil Ceydeli,<sup>1</sup> Tong C. Duong<sup>1</sup> and Robert S. Flowers<sup>2</sup>

<sup>1</sup>Plastic Surgery Institute & Spa, Lynn Haven, FL, USA

<sup>2</sup>Flowers Clinic, Honolulu, Hawaii, USA

## Introduction

Upper eyelid surgery is one of the oldest and most common surgical procedures. Descriptions of eyelid surgery were recorded in Indian *Sanskrit* texts more than 2000 years ago.<sup>1</sup> Such eyelid surgery is consistently one of the most common reconstructive and appearance-related procedures and is performed throughout the world. But many people doing this operation are mistaken about its simplicity, as well as the common complications that may be expected when it is done without proper knowledge, training and understanding of the operation and its potential outcomes.

Upper blepharoplasty can indeed be performed under local anaesthesia, and in an office setting. Yet surgeons should not underestimate this detail-oriented, complication-prone procedure as quick and easy because it looks and seems simple. It can, in selected cases, be done in a short period of time, and is widely considered a relatively quick procedure, with a reliable source of insurance income generation in some countries. But we, as surgeons must not fail to choose the needed and indicated (and perhaps more complicated – and longer) periorbital operation(s), in favour of the one that seems quicker, simpler and predictably paid for by third parties.

## Indications for surgery

Upper eyelid surgery is done for both functional and appearance reasons. Visual fields are profoundly affected by the upper eyelids, either by excess tissue weighing down on the lids and lashes, or by the attenuation of eyelid – and brow – muscles causing droopy eyelids. Commonly the brow and forehead play a major role in functional and appearance, in lid deformity, lid asymmetry and eyelid ptosis, both unilaterally and bilaterally, often making the corrective operation more complicated functionally, aesthetically (and financially).

Cosmetic and functional correction of baggy eyes is sought by addressing the amount of eyelid, brow and forehead skin

excess, the position of the lid crease, the tilt of the eye, any bulging puffiness, hollowness and other potential asymmetries. This is usually done by carefully examining the patient who is seated vertically, directly in front of the examining surgeon.

Diagnosing lid ptosis preoperatively is important. In the senior author's (RSF) huge number of courses on lid surgery taught around the world, he would traditionally start by asking the class for the most common cause of postoperative lid ptosis. The answer was so simple, but never answered correctly – except by an occasional former student. The most common cause of postoperative ptosis is ... undiagnosed preoperative ptosis. Simple but true.

Another way to separate true ptosis from the weight of the brow causing one or both lids to sag, is to simply elevate the brow slightly with a finger, and see if the lid ptosis disappears. Doing this bilaterally can also make the surgeon aware of unrecognized lid retraction, hidden by brow ptosis, which could result in a most unattractive outcome from lifting the brow.

## Preoperative evaluation

Good preoperative evaluation is the key to achieving great results with blepharoplasty. The periorbital region should be evaluated as a whole, including the brow position and lower eyelid characteristics. The effects of adjacent structures such as eyebrows (and sometimes lower eyelids) on the upper eyelids should be pointed out to each patient. Commonly a person's right brow is lower than their left (more than 80% of the time in senior author's personal experience) with the patient's left being lower in only 10% of the time, and the brows proving equal in approximately 7%. These statistics do vary some degree between ethnicities. Know, for sure, however, that upper blepharoplasty does not correct eyebrow ptosis, nor can it overcome any imperfection of the lower eyelid and the orbital bone structures. The senior author pointed out many years ago the importance of combining frontal lift with upper eyelid surgery for the best eyelid results in many, if not most, eyelid patients, while occasionally choosing browlift alone to clean up the brow, lids and upper orbit.<sup>2</sup>

Often we use that same brow access to restore youthful characteristics of the lower lids (via canthopexy into the bone) for canthal restoration and lower lid correction.<sup>2,3</sup>

Careful and thorough preoperative evaluation identifies the problems applying to each selected patient, and a surgical plan is crafted accordingly. General physiology of the eye, such as tearing, dry eyes, increased globe tension (diagnosed with a simple tenometer test) and careful diagnosis of globe protrusion is essential. Consultation assuring appropriate candidacy for surgery, confirmed by a friendly ophthalmologist, should be sought when deemed appropriate. General health conditions are also important considerations to ensure the patient is a good surgical candidate for elective surgery, with minimal risks of bleeding, infection, abnormal scarring and adverse medical complications.

Few eye surgeons understand how and why women in particular *always* raise their eyebrows, smile slightly and tilt their heads posteriorly every time they look into a mirror, or have someone look directly at their face, as well as each time a camera is pointed toward their face (especially in the doctor's surgery). Because of this, we rarely have accurate preoperative and postoperative pictures by which to gauge the way our patients look before we do their surgery. As well as hindering our assessment of their postoperative appearance, this behaviour leaves us uncertain of the quality of our patients' surgical results. A large number of patients seek out plastic surgical repair because of a coincidental snapshot looking so different from their expressions and looks in professionally prepared photographs, or their own glances into the many mirrors before which they have posed each day.

Eyelid surgery is commonly referred to in fashion magazines as 'eye lifts'. In general, 'eye surgery' is anything but a 'lift'! Brows are continually and commonly raised to the patient-learned attractive level, even in youthful people. This is done not only to raise the eyebrows and keep them from interfering with vision, but also to convey a more attractive, more youthful 'look'. This is especially significant when being looked at and scrutinized when looking into a mirror, or being 'captured' by a casual camera.<sup>3</sup> As mentioned earlier, excision of eyelid tissue encourages the brows to drop, exaggerating that look the person has tried so hard to prevent – looking older, more tired and angry as well. This detrimental appearance is caused by a relaxation-drop in the lateral-upward pull of the frontalis muscle (relaxation of which is responsible for creating a frown), which inserts primarily into the central third of the brow musculature. This lessens the upward pull of the frontalis muscle, allowing a greater prominence of the now less opposed frown activity of the corrugator musculature, causing exaggeration of the frown, while the brows (especially in their medial aspect), and often the upper lids come plummeting down too.

From time to time we see elderly patients in whom maximal brow elevation is still insufficient to have comfortable forward vision, even with the head tilted backwards. In these patients significantly large amounts of upper lid-juxta-brow skin can

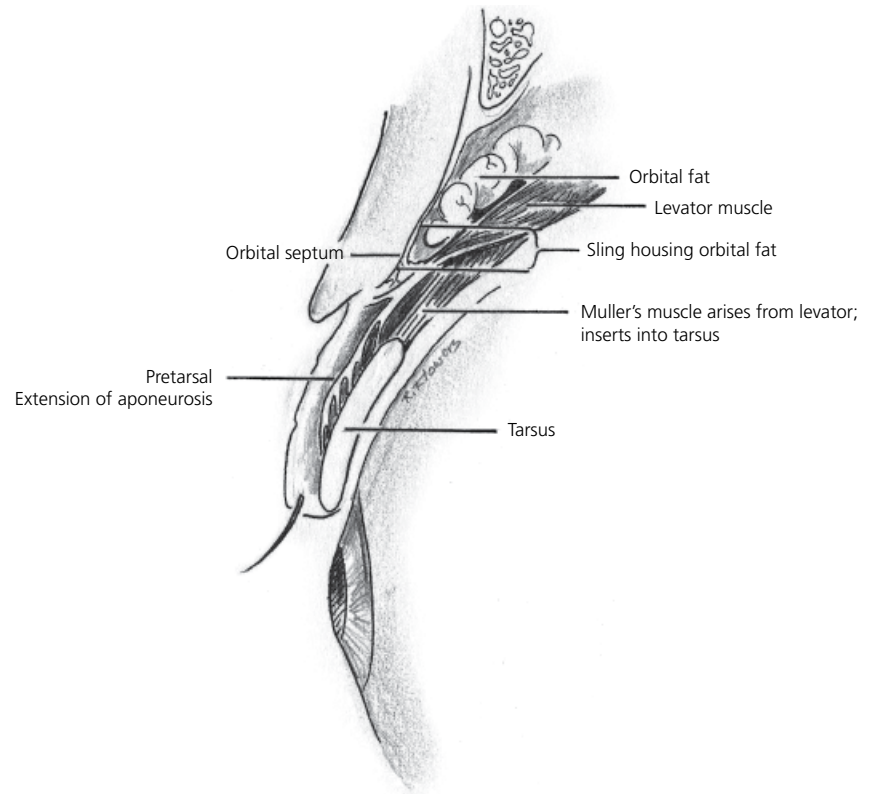
often be sacrificed, allowing the patient's profound brow elevation to now have a sufficient effect to have good forward vision. In these patients simple upper blepharoplasty, often exaggerated, is of immense value, even when the brow eventually drops a bit. These patients will be 'blepharoplasty happy', and some even experience significantly improved facial appearance!

In less elderly people the more lid skin removed, the more the brow will drop (making the person look older and more tired) as well as allowing the relaxation of brow, making that same person look more angry and unhappy. The one positive feature is that transverse forehead wrinkles generally diminish to some degree, often enough to significantly benefit a person's looks, and that alone does a great deal to counteract the old, tired and often angry appearance.

One can observe this phenomenon by having the patient sit relaxed in front of you, with eyes closed. Gently stroke the brow and you will see the frown quickly develop as the brow relaxes. When the patient is totally relaxed, note (and record) the symmetry of the eyebrows, and then press the brow skin firmly down against the skull. Holding tight, ask the patient to open his or her eyes, and carefully notice how far caudal the brow is capable of descending by blocking elective brow and lid elevation. This type of examination shows the surgeon where the greater problem commonly lies – in correcting brow position rather than in excising seemingly excess lid skin. This is true for patients as young as in their twenties, thirties and forties, or even in or before their teens. Performed well, browlifting is often far more important than correction of the upper lids, but generally a lot more expensive! Realize, however, that in many patients, especially older ones, lid tissue removal is an important part of the repair, but more so when combined with brow and/or frontal lifts. Remember, if you do nothing to correct the brow, your result is likely to be disappointing to both you and your patient.

## Anatomy

The upper eyelid has eight layers that are relevant to surgery, from superficial to deep: skin, orbicularis muscle, preseptal or retro-orbicularis oculi fat, orbital septum, orbital fat, levator palpebrae muscle/aponeurosis, Müller's muscle/tarsal plate, and conjunctiva (Figure 68.1).<sup>4</sup> The lacrimal gland lies at the same depth as orbital fat, and it is considered as contained in the lateral compartment, whereas orbital fat is organized into medial and middle compartments. The pretarsal portion of skin adheres to underlying layers through a series of septa, forming the eyelid crease and fold, which may be absent in East Asian patients; creating or adjusting the eyelid crease is performed with this adhesion in consideration. The palpebral muscle and Müller's muscle determine the degree of eyelid opening, with somatic nervous control for palpebral muscle and autonomic control for Müller's muscle; correction of ptosis involves these muscles. Orbital fat and preseptal fat contribute to the bulging and puffiness of the eyelid. The line where the orbital septum



**Figure 68.1** Essential surgical elements of upper eyelid anatomy.

fuses with levator muscle creates the depth of the upper eyelid, which can appear hollow if this line is retracted. The surgeon should keep in mind the correlation between these anatomical structures and the eyelid appearance and function while performing the art of upper eyelid surgery.

## Operative techniques

The operative techniques should address the concerns detected in the preoperative evaluation, layer by layer of the eyelid.<sup>5</sup>

### Skin incision and excision

Mark the incisions while the patient is sitting upright. The amount of skin excision will depend on whether a browlift accompanies the upper eyelid surgery or not. Try a combination of a frontal lift with upper blepharoplasties, when possible, to achieve better outcomes. Know that only about 1 out of 10 patients have brows that do not drop precipitously as a result of eyelid skin excision.

Marking is done prior to local anaesthetic infiltration, first with eyes open and the patient sitting up for determination of the level of eyelid and brow ptosis (as described earlier), then with eyes closed while the patient is lying down in relaxed position. The skin incision line (eyelid crease line) is marked along the natural line of the eyelid; positioned at the desired level of the eyelid crease, usually 7–9 mm above the lash line in women

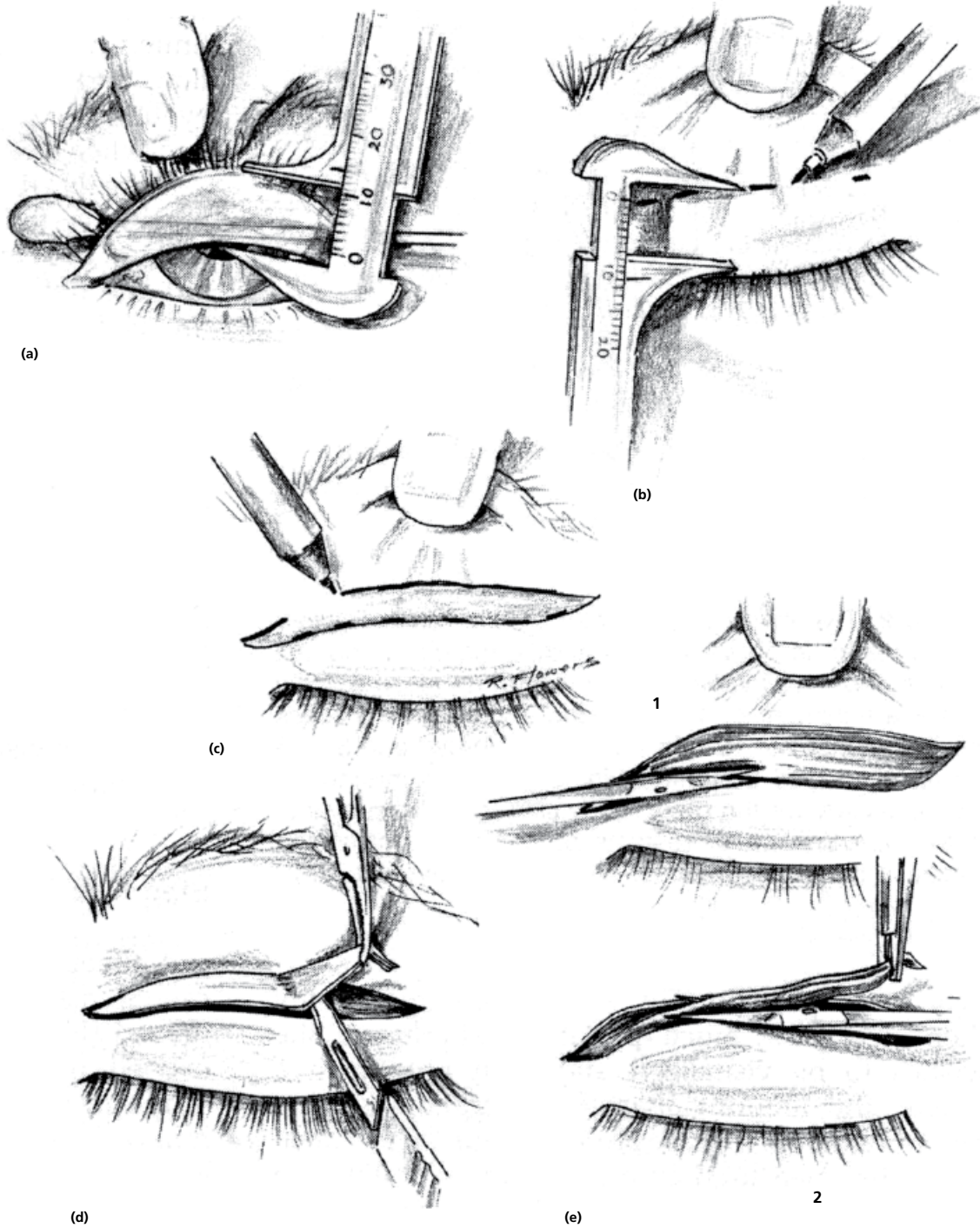
and 5–7 mm above the lash line in men. It is curved superiorly at the lateral ends to provide the pleasing upward slant and to avoid puckering or ‘dog-ear’ formation distally (Figure 68.2a,b). The amount of excess skin to be removed is commonly estimated by pinching with a fine forceps above this incision line at mid-pupil vertical axis and tapered toward both ends (Figure 68.2c). Symmetry of the pretarsal lid segments (lash margin to lid crease distance) is much more important than symmetry of lid crease to brow distances.

One should always keep in mind the position of eyebrows. If a browlift does not accompany the upper eyelid surgery, then more skin and orbicularis muscle should be removed on the side where the brow is lower to compensate for the asymmetry caused by brow location (Figure 68.3).<sup>5</sup> But the more lid skin excised, except in the elderly, the greater will be the brow drop, and the more lid and brow excision necessary to visualize the juxta-brow covered eyelid and pretarsal lid skin.

Lidocaine (lignocaine) 1% with 1:100 000 adrenaline (epinephrine) is the usual local anaesthetic, injected subcutaneously at the beginning, with additional injection as needed when dissection is carried to deeper layers.

### Orbicularis muscle layer

A strip of muscle along the incision can be excised to reinforce the new position of the eyelid crease, or to create a crease for those who do not have it. The sliver of orbicularis muscle excision should occur separate from the skin excision (Figure 68.2d).

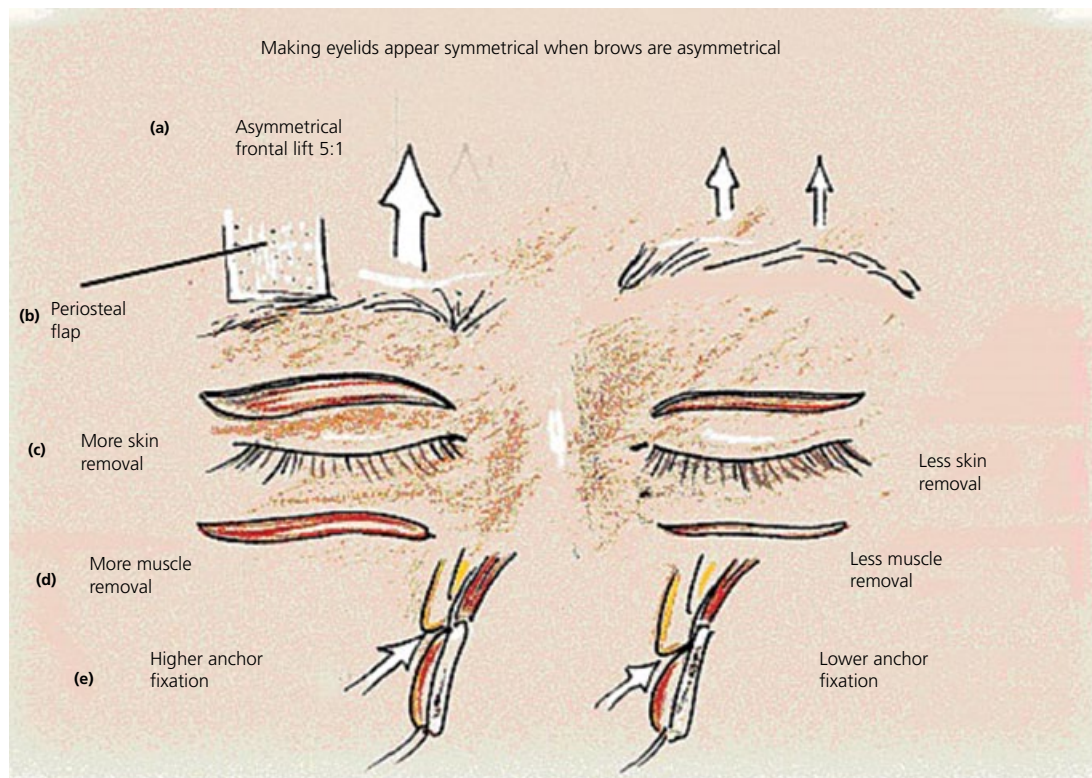


**Figure 68.2** (a) At the beginning of procedure, turn the lid over and measure the tarsus. (b) With the skin under uniform tension, mark the lower skin incision with a Jameson caliper. Usually the height of pretarsal skin incision mark is less than the height of the tarsus. (c) Mark the upper skin incision. (d) Skin excision occurs separate from the orbicularis muscle excision. (e) Remove sliver of orbicularis muscle carefully. Never tent the muscle up during excision for fear of inadvertently transecting the aponeurosis.

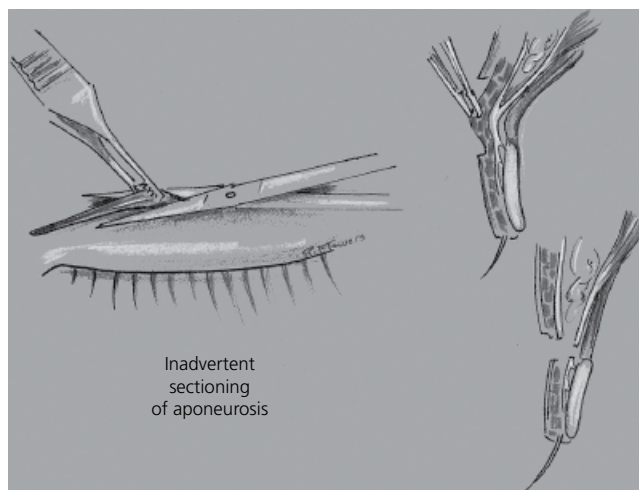
Make sure you do not injure the aponeurosis when trimming the muscle. One must never tent the muscle up during excision for fear of inadvertently transecting the aponeurosis (Figures 68.2e and 68.4). A larger strip of muscle can also be removed to reduce

any existing looseness or redundancy. This step can be bypassed if there is no need to adjust the eyelid crease or muscle excess, and access to orbital fat is achieved by splitting the muscle layer at respective compartments in that case.





**Figure 68.3** Different ways to correct eyelid asymmetry due to asymmetrical brow position. (a) Asymmetrical frontal lift. (b) Insert a superiorly based periosteal flap into the junction of the middle and lateral thirds of the brow which is lower. (c) Excise more lid skin on the side of the lower brow. (d) Excise more muscle on the side of the lower brow. (e) Make the pretarsal skin segment taller on the side of the lower brow, and anchor it at the higher level into the tarsus or the aponeurosis or both.



**Figure 68.4** Inadvertent injury to levator aponeurosis during orbicularis muscle excision, when the muscle is mistakenly tented during excision.

### Preseptal and orbital fat layers

Orbital fat is approached through openings on the orbital septum, although care should always be taken to open the septum in a way that preserves maximum length of the aponeurosis (Figure 68.5), or at least of the septo-aponeurotic extension

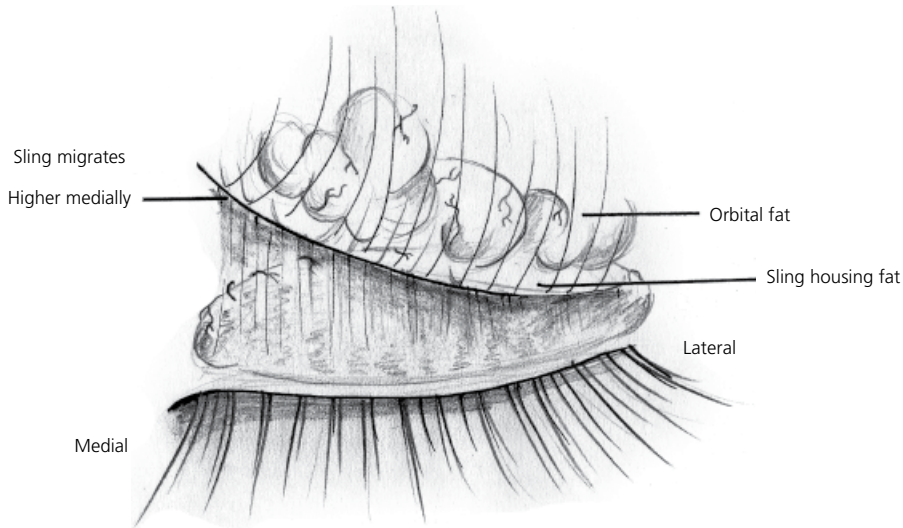
thereof, to assure a proper connection without creating lid retraction. The orbital septum should be entered laterally to prevent damage to the aponeurosis, which may cause further lid ptosis. The septo-aponeurotic sling that houses the orbital fat descends lower laterally, and migrates cephalad nasally. If this direction of sling is not appreciated, an attempt to open the septum across the lid is likely to sever the aponeurosis instead. Once the orbital septum is open across the lid, then the fat excision is quite simple. Be conservative! The baggy and puffy appearance of upper eyelid can be softened with conservative removal of excess preseptal and orbital fat. (Figure 68.6).

### Lacrimal gland

The lateral bulging of upper eyelid can be a result of a sagging lacrimal gland. The orbital lobe of the lacrimal gland can be sutured to the periosteum lining the inner side of the superior orbital rim to correct this appearance.

### Levator muscle and orbital septum

Preoperative diagnosis of lid ptosis is essential. Ptosis caused by attenuation or laxity of levator muscle can be corrected with imbrication of the muscle to the superior edge of tarsal plate, using interrupted absorbable suture such as 6-0 Vicryl or PDS. This manoeuvre also brings the orbital septum–levator muscle



**Figure 68.5** The septo-aponeurosis sling housing the orbital fat descends lower laterally and migrates cephalad nasally. If this direction of sling is not appreciated, an attempt to open the septum across the lid may sever the aponeurosis instead.

fusion line forward, softening the hollowness of the upper eyelid. In case of severe upper lid hollowness, tighten the suspensory ligament of the globe with the same orbital rim suture used in the canthopexy, commonly described in the senior author's publications and many lectures and courses. This is the best treatment when the thickening on the orbital septum between medial and middle compartments is weakened by ageing or previous surgery. Tightening the orbital septum with the same canthopexy suture gives additional tightness to the lower lid, which lifts the globe and tightens the lower lid and orbital contents significantly, pushing on and lifting the upper lid fat so it fills out the hollowing of the upper lid that frequently accompanies ageing, especially when accompanied with weight loss.

### Closure of incision

The incision is closed simply with a running suture. Another advantage of simple running closure is the ability to recreate or further define the lid crease by incorporating the edges of the aponeurotic tabs into the skin closure across the lid (Figure 68.7).

### Examples

Examples of upper blepharoplasties and coronal browlifts are shown in Figures 68.8 and 68.9.

### Postoperative care

Patients should be advised to sleep at 45° head elevation post operatively. This diminishes the swelling, which can be significant for the first three weeks. To minimize the early excessive swelling, compressive bandage can be used overnight for periorbital protection, although this will blindfold the patient, and may not be well tolerated by some. It does, however, speed up the recovery and minimize haematoma. Cold compressions should be used for the first few days after the

bandages are removed to further control the swelling. They need not be used for longer than 2 days. Usually the swelling has diminished by around two weeks, however rarely it may last longer than several weeks.

Patients should avoid any vigorous activity for several weeks, with no sudden increase in heart rate and blood pressure, thus minimizing the risk of postoperative bleeding.

Pain is usually minimal, and well tolerated with paracetamol.

The sutures are usually removed within 5–7 days, and the patient should avoid rubbing the eyes, so the fine sutures are not loosened or broken within the early stage.

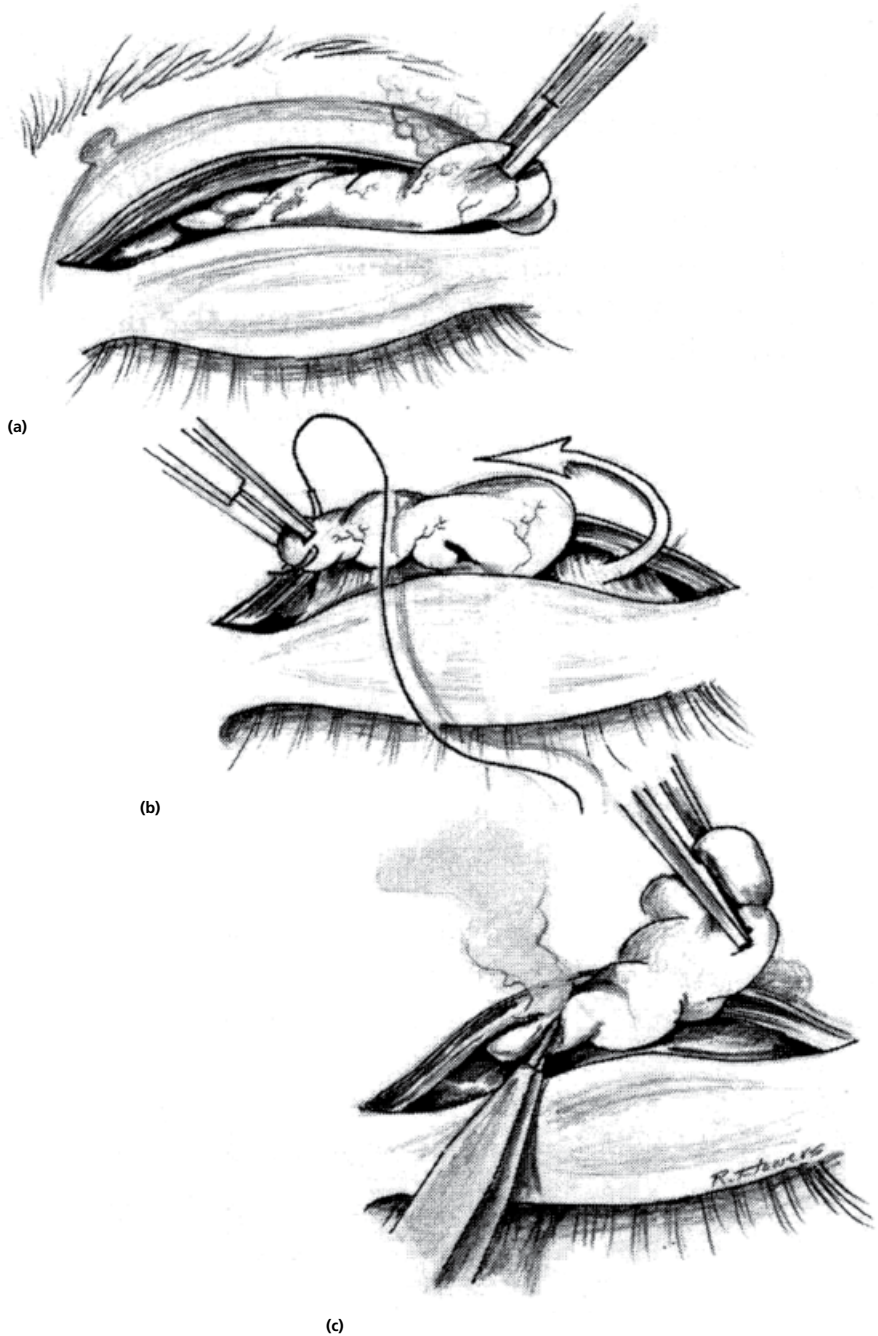
During the first week or two, ophthalmic ointment should be used, particularly at night, since most patients are unable to close the lid fully (postoperative temporary lagophthalmus) due to early tightness on the lid as well as swelling.

### Complications

Complications of eyelid surgery are usually due to bleeding, transient disturbances in tear mechanism and excess skin excision. Good compressive overnight bandaging diminishes bruising, swelling and damage, as does avoidance of rubbing of the eyes.

### Haematoma

Superficial haematoma usually occurs when a patient experiences a surge in blood pressure, such as during vomiting, coughing, straining, pain or anxiety. Some over-the-counter medications, such as aspirin or ibuprofen, taken inadvertently, could contribute to this complication. Haematoma that appear to extend posterior to the orbital septum must be addressed urgently, with exploration under good light for irrigation and haemostasis. Ice compresses, head elevation and pain medication are some routine measures that might prevent this kind of complication.



**Figure 68.6** (a) Fat excision is quite simple with the orbital septum open across the lid. (b) There is often a prominent tuft of lateral orbital fat tucked behind the orbital rim, next to the lacrimal gland. This fat may be excised, or it may be transposed into the hollow defect. (c) Careful haemostasis is performed with bipolar cautery.

### Subconjunctival haemorrhage

This is a collection of blood under the conjunctiva; it is usually absorbed in 10–14 days. Irritation and tearing can result from this condition. Ice saline compresses, artificial tears or ocular lubricant can keep the patient comfortable until resolution.

### Conjunctivitis

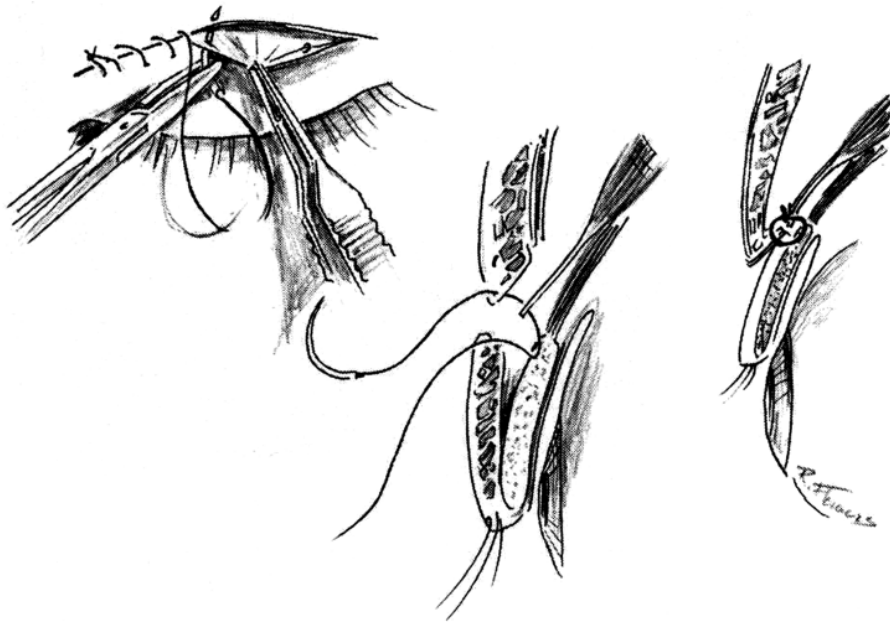
Inflammation of the conjunctiva can be from sutures, blood clots, pieces of tissue, corneal abrasion or infection. A severe reaction to light suggests corneal abrasion, and examination with

fluorescein should be done. Obvious pus should be cultured. Artificial tears and ocular lubricant are used for inflammation without infection. Antibiotic drops such as Sulfamyl or antibiotic ointment such as bacitracin can be used for infection. An eye patch provides relief for corneal abrasion or severe irritation.

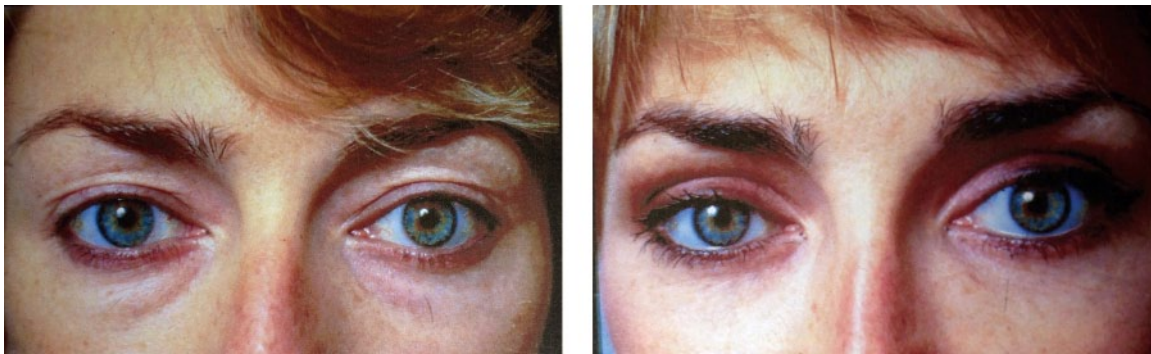### Abnormal tearing

The tearing mechanism may need some time to return to normal functioning after surgery. During the first couple weeks post-op, patient may experience excessive tearing (epiphora),





**Figure 68.7** Skin closure and recreating or further defining the lid crease by incorporating the edge of the aponeurosis into the skin during closure.



**Figure 68.8** Isolated upper blepharoplasty. Before and after pictures. (Performed by RSF.)

dry eye syndrome and visual blurring. Symptomatic treatments with artificial tears, lubricant and patching usually resolve the condition over time.

### Lagophthalmos and ectropion

Lagophthalmos is a condition where an eyelid cannot close completely. If this occurs post operatively, it may mean that too much skin has been removed. Often patients can tolerate 1–2 mm lagophthalmos, but 2–3 mm can lead to desiccation of the ocular surface. Factors causing lagophthalmos are excess skin excision, weakness of orbicularis muscle, paralysis of the temporal branch of the facial nerve, tethering of the eyelid to deeper structures or bad scar formation. Initial treatments include the usual supportive measures of artificial tears, ocular lubricant and eye patch; and stretching eyelid massage.

Ectropion is the turning outward of the eyelid, exposing palpebral conjunctiva. This condition is the result of excessive removal of skin, especially in patient with pre-existing laxity of eyelid. Treatments are similar to those for lagophthalmos.

### Profound drop of brows and accentuation of corrugator frown

This commonly occurs after upper blepharoplasty when compensated brow ptosis is not recognized before surgery, and simultaneous or planned browlift is not incorporated into the plan.

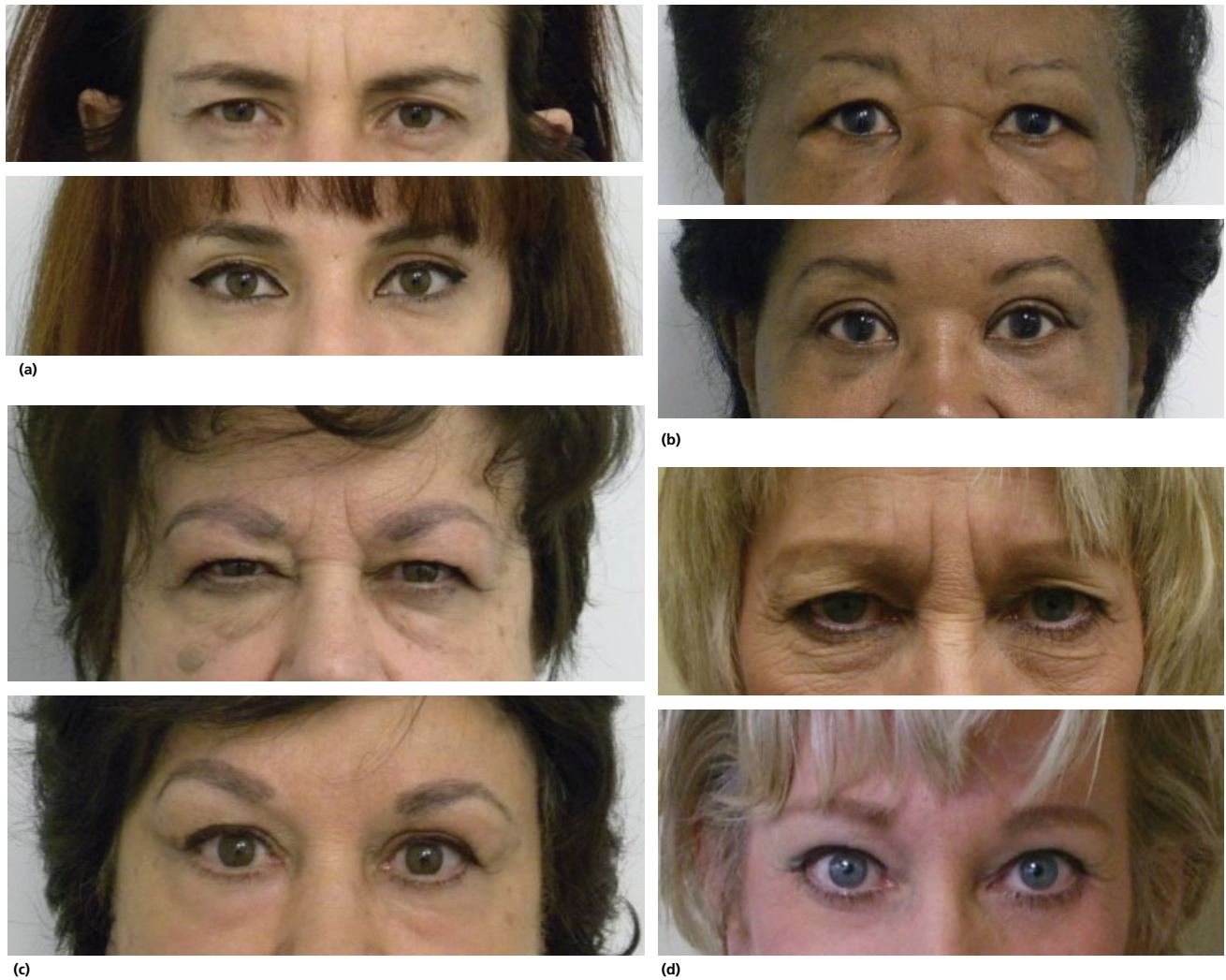### Asymmetry

Failure to recognize brow ptosis preoperatively, failure to accurately measure and mark the skin for the lid incision and skin excision, failure to recognize and compensate for asymmetrical eyelid ptosis are all causes of postoperative eyelid asymmetry. The most important manoeuvre to minimize this happening is a superb preoperative exam, and careful marking and planning.

### Lid ptosis

Varying degrees of lid ptosis are common in the early postoperative period due to swelling, usually subsiding without intervention. The commonest cause of persisting lid ptosis after





**Figure 68.9** Upper blepharoplasty and coronal browlift. Before and after pictures. (Performed by AC.)

surgery is undiagnosed preoperative ptosis, which is often exacerbated in the early postoperative period by stiffness and increased weight of lid oedema. If the preoperative ptosis is not well documented and pointed out to the patient, the postoperative ptosis will inevitably be blamed on the surgeon. Another common cause of ptosis is iatrogenic injury to levator muscle or aponeurosis, commonly caused by careless lifting of the tissue while excising a strip of orbicularis muscle. Bleeding to Müller muscle may also cause prolonged ptosis.

### Conclusion

Upper blepharoplasty can be a splendid operation when done by skilled surgeons on the right selection of patients, under the correct conditions. The operation usually occurs under local anaesthesia, assisted by light oral or intravenous sedation.

Good outcomes soar after upper blepharoplasties, especially when combined with skilled browlifts, and even more so when globe-lifting lower lid-tightening procedures are added.

### References

- 1 Bhashagratna KK. *An English Translation of the Sushruta Samhita, Based on Original Sanskrit Text*. 3 Vols. Calcutta: Bose; 1916.
- 2 Flowers RS, Ceydeli A. The open coronal approach to forehead rejuvenation. *Clinics in Plastic Surgery* 2008;35(3):331–351.
- 3 Flowers RS, Ceydeli A. Mag-5: A magnificent approach to upper and mid-facial 'magic'. *Clinics in Plastic Surgery* 2008;35(4):489–515.
- 4 Zide B, Jelks G.W. *Surgical Anatomy of the Orbit*. New York: Raven Press; 1985.
- 5 Flowers RS, Lueprapai M. Blepharoplasty in the East Asian patient. In: Aston SJ, Steinbrech DS, Walden JL (eds), *Aesthetic Plastic Surgery*. New York: Saunders; 2009.