

The Open Coronal Approach to Forehead Rejuvenation

Robert S. Flowers, MD^{a,*}, Adil Ceydeli, MD, MS^{a,b}

KEYWORDS

- Brow lift • Frontal lift • Coronal lift • Forehead lift
- Forehead rejuvenation • Upper blepharoplasty

A well-done coronal lift is in the authors' opinion the best single operation in aesthetic surgery. Not only does it produce awesome results in and of itself, it also provides optimal access for the best possible, and longest-lasting, midcheek lift, corrugator frown removal, and even optimal lower lid blepharoplasty and canthopexy (**Fig. 1**). A thorough exploration of these latter aspects, and advantages of the open forehead approach on midface and lower eyelid rejuvenation will appear in the article by Flowers and Ceydeli in *Facelifts*, Part II, in the October 2008 issue of *Clinics in Plastic Surgery*.

For over 39 years, the coronal lift has been the senior author's most common operation, used in a huge number of patients (well up into four digits). The experience has provided insight and expertise on how best to create optimal facial rejuvenation, restoration, and/or transformation (when needed).

It is interesting that it was the quest for the optimal upper lid blepharoplasty that ended up relegating this operation to a one of secondary-to-nonexistent importance, just as the quest for the perfect lower lid blepharoplasty led to its subjugation to a secondary roll, secondary in significance to support oriented endeavors, such as the extremely effective two-layered (osseo-orbicularis) canthopexy and the midcheek lift.

WHEN AND WHY BROW LIFTING INSTEAD OF UPPER BLEPHAROPLASTY

People undergo blepharoplasty in a quest to correct a baggy aging look around their eyes. In

90% or more of persons having blepharoplasty, the primary need was frontal lifting, or brow elevation, occasionally with a very conservative accompanying upper lid blepharoplasty. Instead, the primary focus was tissue removal from the upper lid, with precious and irreplaceable eyelid skin being sacrificed, usually in huge quantities. This inevitably causes the brow to drop, whereupon more lid skin is sacrificed, and this often followed by a third session. By the time someone recognizes the uncorrected brow as the real problem, there is insufficient lid skin left to do a forehead or brow lift, and insufficient lid skin remaining for a normally functioning eye (at least 29 to 30 mm of skin needs to remain between the unaltered lower margin of the central eyebrow and the lid margin) (**Fig. 2**). The brow now has dropped precipitously, and instead of looking brighter, fresher, and more youthful as anticipated, the operated person looks older, more tired, and angry. The brow drop and exaggerated frown occur because the previously contracting frontalis muscle, working nonstop, but subconsciously, for 16 to 18 hours a day elevating the ptotic brow and providing comfortable and unobstructed forward vision (a phenomenon the senior author designated "compensated brow ptosis")^{1,2} takes advantage of this opportunity to relax and conserve energy. The brow drops, but the frown also accentuates, because relaxation of the frontalis muscle decreases its pull against the glabellar skin and relaxes its antagonist action in opposing corrugator muscle activity. (This phenomenon is easy to observe on most people

^a The Flowers Clinic, 677 Ala Moana Boulevard, Suite 1011, Honolulu, HI 96813, USA

^b Bay Medical Center, 801 East 6th Street, Suite 302, Panama City, FL 32401, USA

* Corresponding author.

E-mail address: flowers@flowersclinic.com (R.S. Flowers).

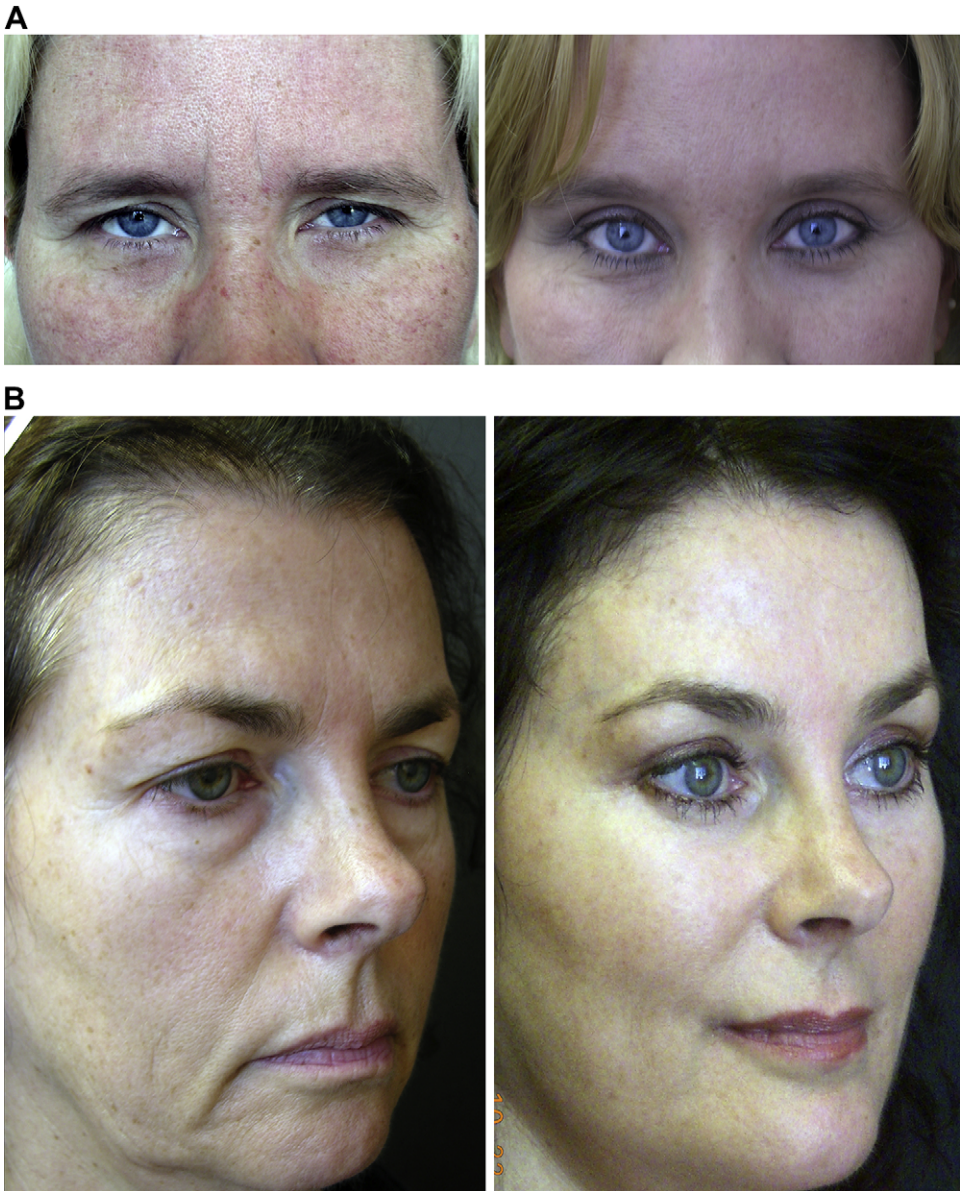

Fig. 1. (A) 42-year-old woman, before and 1 year after coronal lift with corrugator resection. (B) 51-year-old female, photographed before and 1 year after Mag-5 (coronal lift with corrugator resection), two layered lateral canthopexy to, and into, bone, with lower blepharoplasty and midcheek lift, comprised of periosteum and orbital septum, orbicularis muscle, subcutaneous tissue, and skin, with extra support from a 3-0 Vicryl secured through a drill hole into the malar tuft.

when they close their eyes and relax their foreheads.) With the patient thus relaxed, firmly compress his or her forehead skin, just above the brow against the bone, immobilizing it. Do not press downward, but with the mirror in front of the patient and his or her head in a neutral position have the patient attempt to open his or her eyes. The frown is visible; the brow and juxta brow overhang is evident, and it is quite clear that the pathology is the brow not the upper eyelid (**Fig. 3**).

Upper lid surgery in the presence of compensated brow ptosis could be the most mistreated and misdiagnosed condition in surgery. Just because a patient asks for an operation, or because insurance is willing to defray its costs, is not justification for doing the wrong operation. One never would consider operating on a knee when the problem is the person's hip. Neither should one do lid surgery, when the problem is a ptotic brow.

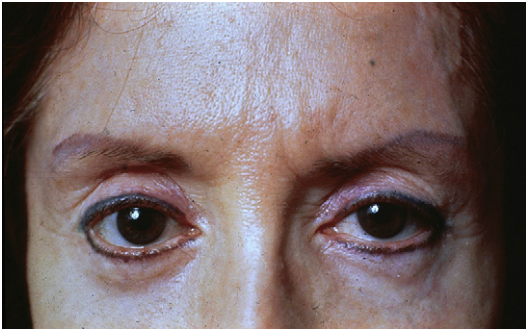


Fig. 2. A patient who underwent three upper lid tissue excisions, creating an uncorrectable deformity, when her primary need was for one simple brow-elevating surgery with corrugator resection.

Earlier the authors stated their opinion that the well-done coronal lift is the best single operation in aesthetic surgery. This might seem a good reason, but it is not an adequate reason to do the operation. The reason one should choose it over upper blepharoplasty is because the coronal is the right and proper choice for the patient's well being, and for optimal outcome.³

It is appropriate that lifts begin at the top.⁴ To lift any part without first making sure the area superior to it is in a proper position is foolish, for it inevitably results in a traffic jam of unattractive crowded tissues at the zone where the lifted encounters the unlifted. This commonly occurs in the zone where the lateral orbital region (eyelids and brow) joins with the temple (**Fig. 4**). That is why a lateral emphasis (preferably open) frontal lift deserves to be a regular part of a surgeon's prescription for facial improvement, whether with midcheek lifts, canthopexies and facelifts accompany, or not.

THE CORONAL LIFT AND OTHER VARIATIONS OF LARGE OPEN FRONTAL FLAPS—KEEPING THEM SIMPLE AND EFFECTIVE

The coronal or frontal lift is a simple operation, but surgeons make it unnecessarily complicated, thereby frightening themselves and patients away from what is a magnificent operation, and the most effective tool for brightening and refreshing appearance. It becomes even more effective when combined with canthopexy and midcheek lifting, and lower lid surgery. Its rejuvenation and

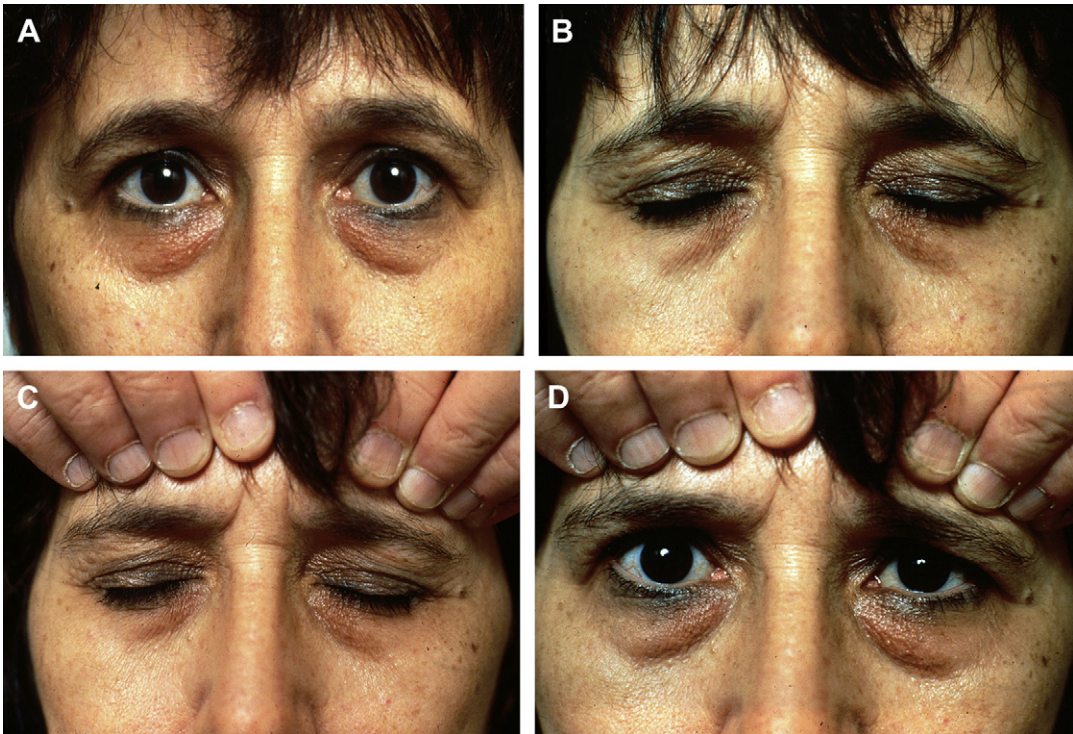


Fig. 3. Sit directly before the patient (A), and (B) have that person close his or her eyes and relax the forehead, with the head in a neutral position. (C) Press the skin just above the brow tightly against the forehead, taking care not to push the brows downward. (D) Resist upward movement of his or her brow with your strong fingers, and have the patient look into a mirror. This will show the patient the nature of his or her pathology, brow versus eyelids.

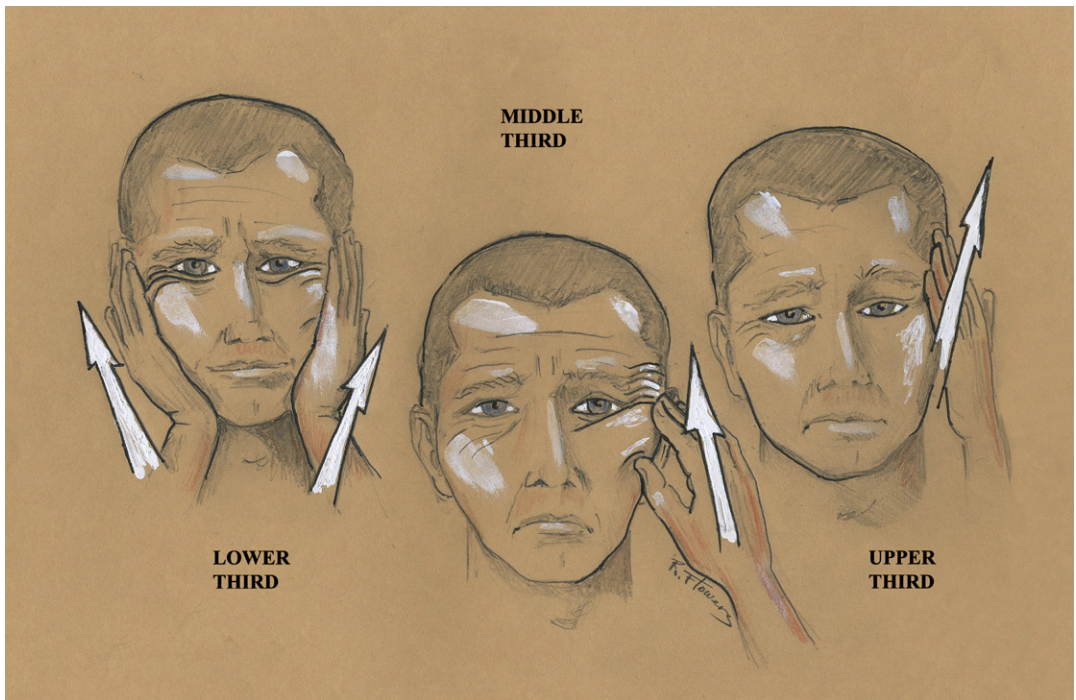


Fig. 4. (Left) Lifting the lower face independently crowds the cheek–lower lid area. (Center) Lifting the midcheek independently crowds the upper eyelid–lateral brow–temple region. (Right) It is therefore best to start lifts at the top to avoid traffic jams or tissue crowding. The upper lift lifts can be done very affectively without exercising any negative affects on the tissues beneath them, and are essential when the area beneath crowds them.

beauty-enhancing effects are awesome, and much of its benefit is transferable to endoscopic lifts or lateral juxta-brow, temple excisions, if one takes the time to master the details.⁵

Even though the coronal lift is awesome in its capacity for improvement, patients rarely request it, and are unlikely to sign up for any type of frontal lift, especially an open one, without sensing a surgeon's absolute conviction of its correctness, and his or her strong desire to perform the operation for the patient's maximal benefit. When offering it to a patient, do so with confidence and conviction. In almost forty years experience with this operation, the senior author has rarely seen this fail.

In the following sections, the authors share their considerable experience on coronal lift to optimize outcome, simplify repair, minimize any morbidity, prolong benefit, and hide the scars.⁶

TECHNIQUE

Hair Control

Hair control is the key element in simplifying an open frontal lift. Surgeons who enjoy the operation have mastered a technique of hair control, and those who have not, generally avoid the operation.⁷

Insist on each patient having a good shampoo the evening before, and the morning of surgery, making sure the hair is dry before the operation begins. Shave a path slightly less than the anticipated area of skin removal (**Fig. 5**). At least 4 cm of hair should remain anterior to the incision after scalp skin removal. Use sterilized autoclave tape to secure the bulk of the hair posteriorly away from the incision (**Fig. 6**). Create bundle twists of the hair anterior to the proposed incision, securing each with two dental appliance-type rubber bands (**Fig. 7**).

Incision

As a general principle, avoid hair perimeter incisions, except at the balding zone in male pattern alopecia, which is also present in one-of-twelve females undergoing the operation (**Fig. 8**). Use a hair perimeter incision centrally only when an extremely high forehead is combined with the need for considerable central brow elevation. A request to shorten the long forehead on a female usually relates to her desire to style her hair swept backwards. This is rarely possible, because the visible scar recommitments the person to wearing bangs, much as the longer forehead did.⁸

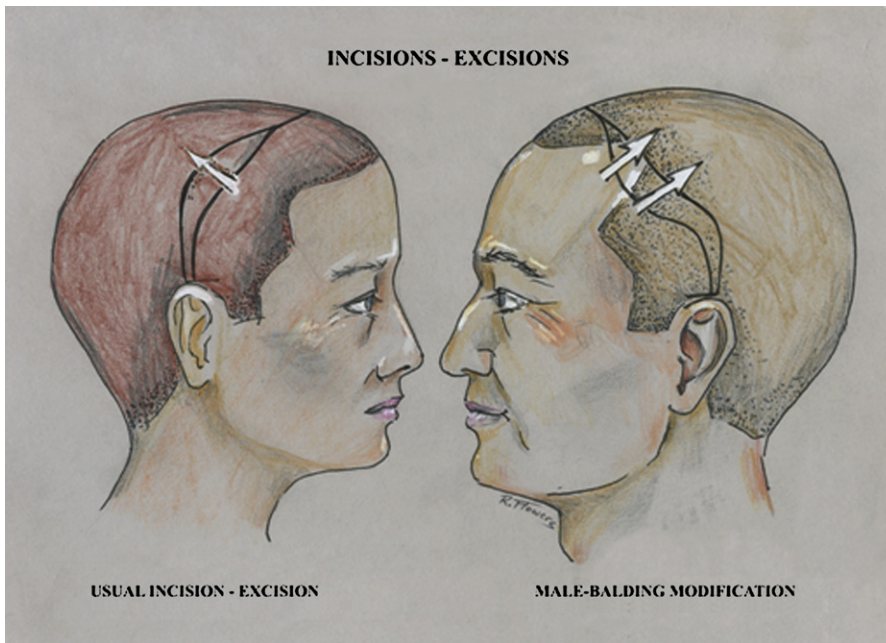

Fig. 5. Incisions (*posterior–superior lines*), and excisions (*the area between the anterior and posterior lines*) for (*left*) normal large flap forehead lift (coronal) and (*right*) male balding pattern modification. Note right angle cuts above the ears and the central cut that ease tension on the forehead flap and simplify turning the flap down.

In the male balding pattern, whether in males or females, the central incision should detour behind the widow's peak area. When complete dome alopecia exists, as often occurs in males, it is usually best to do a true coronal incision (**Fig. 9**) with a central relaxing cut, or else opt for an endoscopic brow lift. Direct ellipsoid forehead skin excisions,

custom-designed for each patient, are also a possibility in these patients (**Fig. 10**).

The coronal incision descends vertically over the temporal region, ending up approximately 2 cm posterior to the central attachment of the ear's upper pole, where the hair grows in a posteriorly directed, but parallel, fashion on both sides of

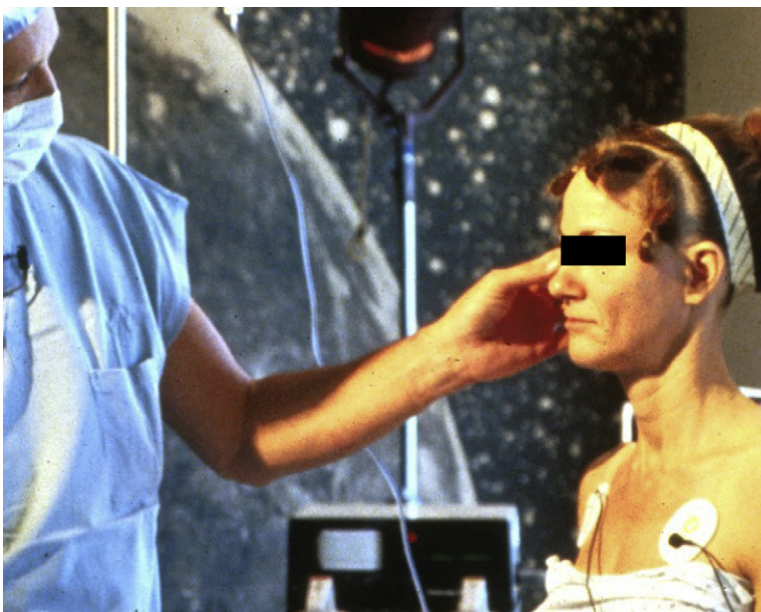


Fig. 6. Patient undergoing final check prior to large flap forehead procedure. Note the sterilized autoclave tape holding the posterior hair in position and the dental rubber band-secured bundle twists controlling the hair anterior to the excision.

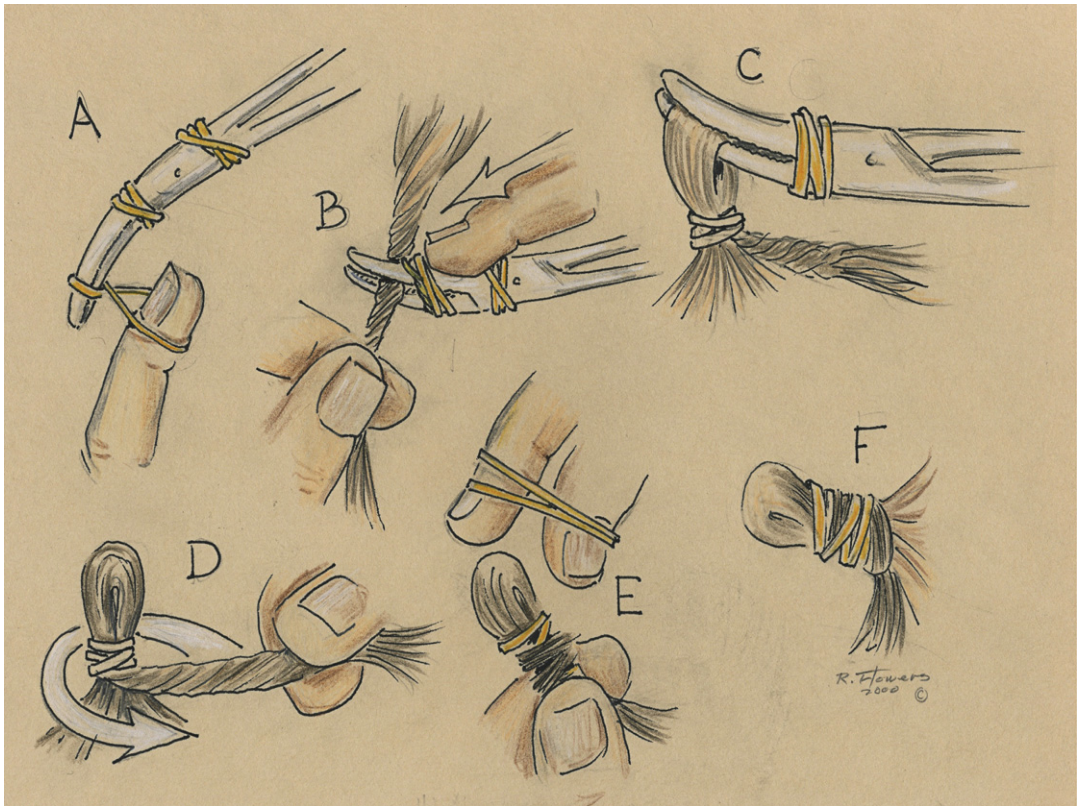


Fig. 7. Anterior (preincisional) scalp hair control for forehead lifting, creating bundle twists of well-shampooed hair with dental rubber band securing them in position. (A) Load a large mosquito clamp with several double-looped bands. (B) Isolate a section of hair; twist it, then slide the loop down over the twist (C), making a loop. (D) Circle the twisted hair around the loop, (E) securing it there with another double-looped dental rubber band. (F) Finalized bundle twist, ready for surgical prep.

the incision (**Fig. 11A**). This location usually avoids the area just above the ear, where there is commonly a transition zone in the direction of hair growth. The excision of just a small amount of scalp in this transitional growth area leaves a part that prominently exposes even a fine line scar. This is because the hair in front of the operative scar grows forward, and that behind grows backwards, betraying the patient's secret. Excision within the transitional hair growth zone always creates a parting of the hair (**Fig. 11B**) that exposes the scar. Excision within the parallel growth zone leaves a well-hidden scar.

Just above the ear, the incision makes a sharp right angle turn, extending anteriorly (see **Fig. 11A**), and advances with an incision bevel matching the hair growth pattern, to a point corresponding to the central attachment of the upper pole of the ear. This facilitates turning-down of the frontal flap. This turning-down can be simplified further by making an anteriorly directed central releasing incision (see **Fig. 5**). The incision never should extend to the hair perimeter. Make

sure that at least 1 cm of undisturbed hair growth hides the anterior extent of that central releasing incision.⁹

Only in very short, and profoundly bald men are coronal scars easily recognized. In these patients, consider endoscopic lifts, ellipsoid forehead excisions (see **Fig. 10**), or even Botox. Even with high foreheads, it is important to avoid hair perimeter incisions (**Fig. 12**).

It is important to bevel the knife parallel to the direction of the hair growth along the entire scalp incision, which minimizes damage to the hair follicles and helps hide the final scar. Applying Leroy-Rainey clips (**Fig. 13**) to the edges of the incision (making sure to include galea) will control the bleeding from the highly vascular scalp, thereby eliminating excessive use of electrocautery, which further decreases the chance of hair follicle injury. Autoclave the clips before their first use, and use the same Rainey clips approximately 10 times. Reautoclaving the clips weakens them, preventing mechanical injury to the hair follicles.




Fig. 8. Use hair perimeter incisions only when extremely high forehead occurs in conjunction with a need for great deal of central brow elevation.

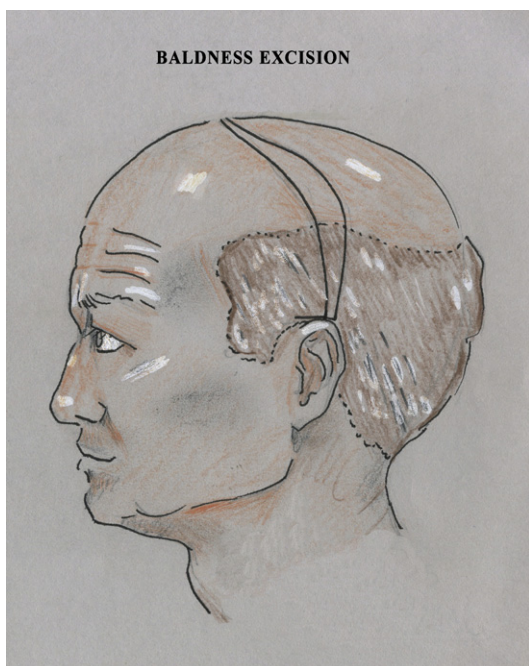


Fig. 9. When complete dome alopecia occurs in men we usually choose a traditional coronal incision or else opt for endoscopic lift or direct, or ellipsoid forehead incisions.

These fine steps, along with avoiding the closure of galea and using only staples for the scalp closure, will decrease the chance of alopecia tremendously.

Dissection

Frontal lifts work best with the dissection just above the pericranium (subgaleal/supra-periosteal), which helps lift the entire anterior scalp complex, together with the lateral brows and temple area.⁸ The dissection also can be carried down over the lateral orbital rim and zygoma to facilitate the canthopexy and midface lift (**Fig. 14**). Supra-periosteal dissection facilitates a more precise corrugator dissection and removal, and better release of the frontalis and corrugator muscle-induced transverse and vertical (frown) forehead wrinkles (**Fig. 15**). It also invites better and more permanent fixation of the recalcitrant lateral brow through superiorly based periosteal flaps (**Fig. 16**).

Continue the dissection at this supra-periosteal level down over the orbit rim, stopping just superficial to the orbital septum. This is especially important laterally, facilitating optimal upward movement of the lateral brow and temple skin. If the surgeon is confident that no additional periosteal flap support is required, then a subperiosteal dissection suffices, so long as it moves supra-periosteal 2 to 3 centimeters superior to the orbital rim. Be aware, however, that leaving the periosteum attached to the scalp flap limits the release of both transverse and vertical forehead wrinkling (see **Fig. 15**).

Some people are at high risk¹⁰ for decreased long-term success in brow elevation operations.¹¹ This group includes men, most of whom have very low brows developmentally (**Fig. 17**), as do some women. It also includes people who have exceptionally high foreheads, requiring concealed incisions to be placed so remote from the brow as to create mechanical disadvantage. Among this group are people who have undergone previous forehead lifts with suboptimal outcome. Secondary lifts can be of considerable benefit to many of these people, especially when the initial lift was sub-periosteal, thus allowing a supra-periosteal redo.

It is the old tethering scar that often resists, and limits, the desired brow elevation in secondary operations. Often the optimal secondary repair is a different type procedure, such as a lateral emphasis juxta-brow, temple lift (see **Fig. 10**). These lifts often extend medially only to the mid-, or midlateral brow. In others, they need to extend more medially. Other times a central excision is

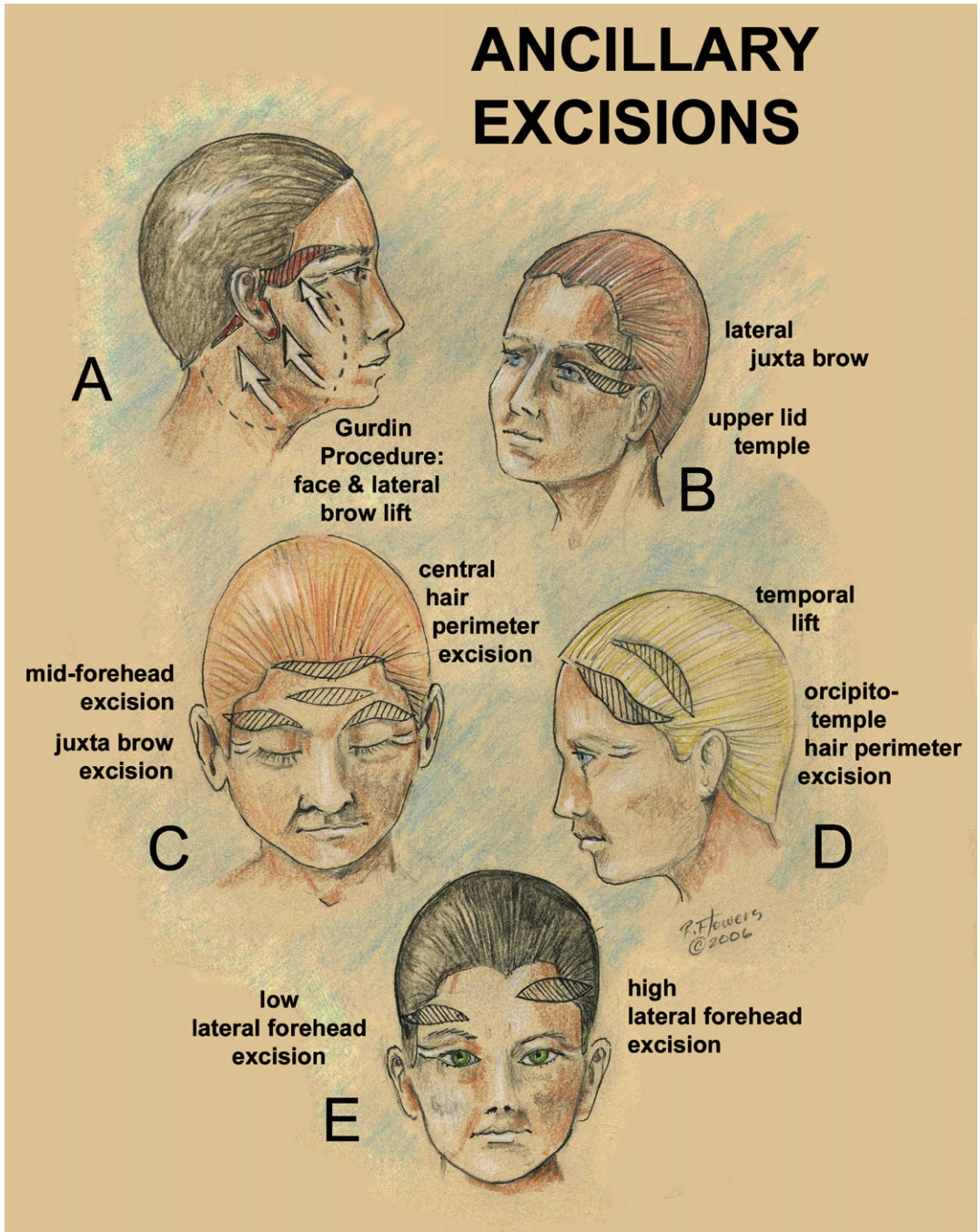


Fig. 10. Direct forehead excisions, custom-designed for each patient, can be extremely beneficial when (A) joining lateral brow lifting butterfly excisions with secondary facelifts, (B) doing lateral juxta brow excisions to provide temple lift when midcheek crowding is insufficiently protected by a coronal or other large flap lift. (C) They are additionally helpful for midforehead excisions to prevent the demonic look deformity resulting from medial brow drop as a result of lateral brow lift, also providing access for corrugator excision, (D) two varying types of temple lifts—hair perimeter excisions and behind-the-hair excisions, and (E) asymmetrical lateral forehead excisions.

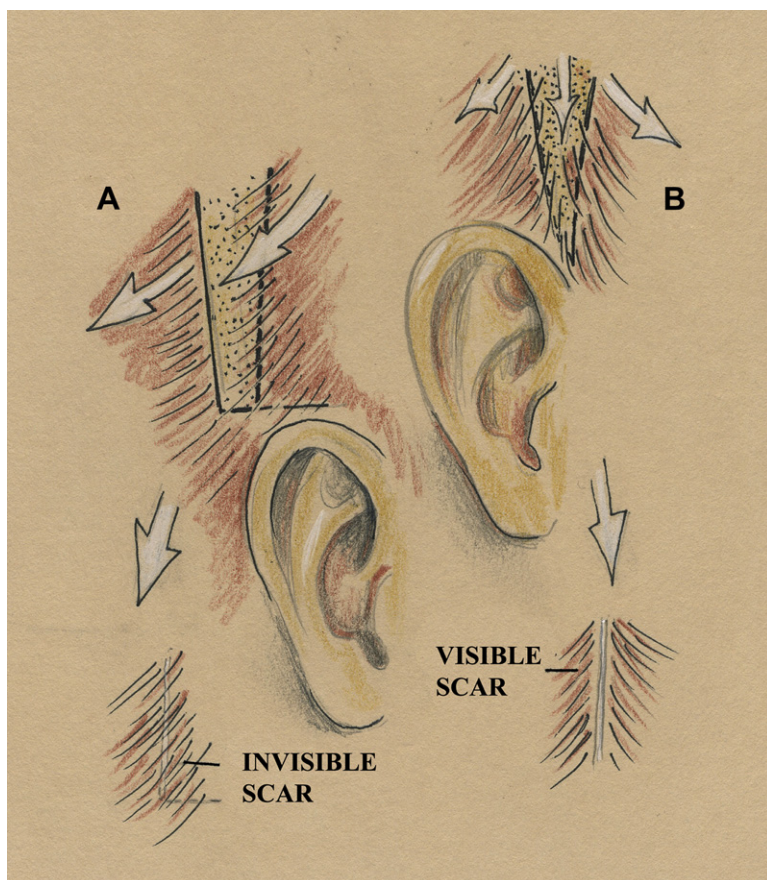


Fig. 11. Scalp excision in a zone of parallel directional hair growth leaves barely perceptible to invisible scars, as on side (A). (B) scalp excision in this commonly transitional growth zone just above the ear results in a hair part and a very visible scar even if the scar is of hairline proportions.

desirable to elevate the central brow. It is best when patients requiring such direct excisions are older, and boast minimally sebaceous skin, both of which limit the visibility of scarring.

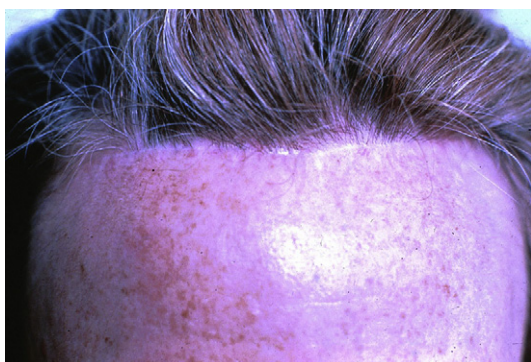

Fig. 12. Try hard to avoid hair perimeter incisions, even in people who have very high foreheads. The common reason people want shorter foreheads is so they can wear swept back hair styles, instead of bangs. But the swept back styles usually do not work because of the visible hair perimeter scars, unless they elect hair transplants, which may, or may not, conceal the scars.

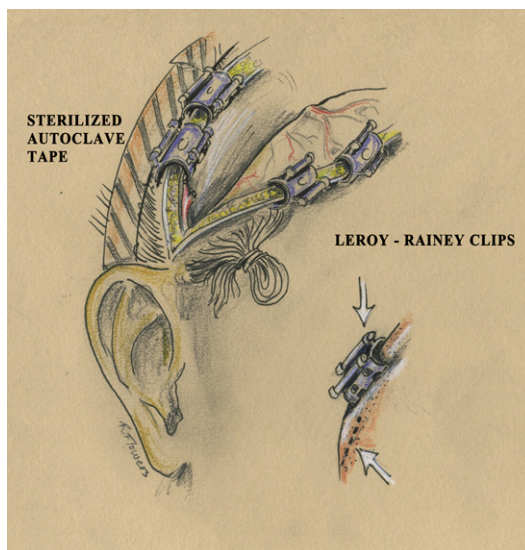


Fig. 13. Application of Leroy-Rainey clips to the wound edges secures good hemostasis, especially if the surgeon engages the galea within the jaws of the clip. Applying the clips in a slightly diagonal fashion along the skin edge, thereby trapping and putting pressure on those vessels running parallel to the wound margin also enhances hemostasis.

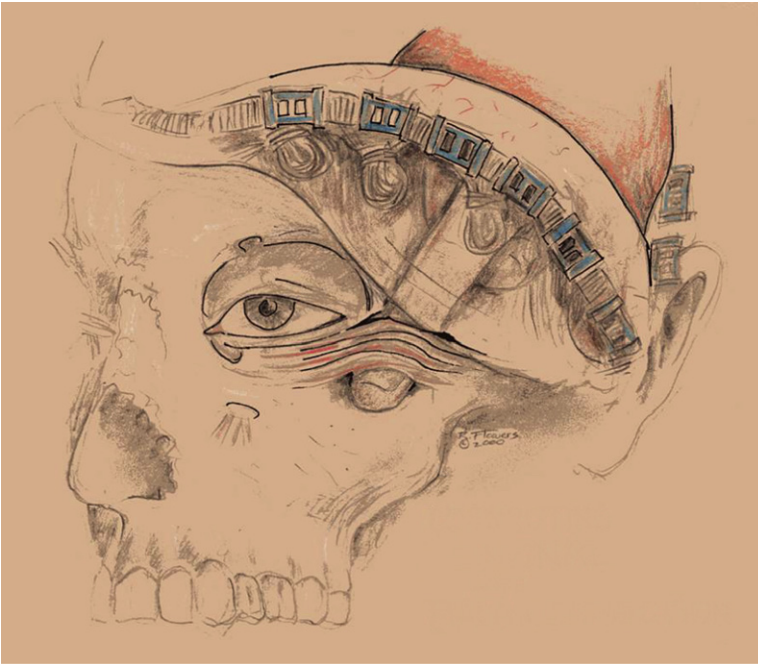


Fig. 14. This drawing depicts the ease of extending the coronal incision down onto the zygomatic and malar complexes, with a generous communication of the two pockets. This does wonders facilitating into-bone and to-bone canthopexies, as well as increasing the quality and longevity of midcheek lifts and the lateral aspect of coronal flaps.

Supra-periosteal dissection not only facilitates more effective corrugator muscle removal, it also simplifies removal of the depressor and procerus muscles when one desires their removal. It also provides a setting that facilitates the use of periosteal flaps in securing the lateral brows at optimal levels.

These superiorly based 2 cm wide periosteal flaps (see **Fig. 16**), when secured into the junction of the middle and lateral thirds of the eyebrow, assist in achieving permanency of lateral elevation, especially when there is significant unilateral or bilateral developmentally low positioning (asymmetrical).

ADDING SECURE LATERAL SUPPORT TO THE LIFT BY SUPERIORLY BASED PERIOSTEAL FLAPS TECHNIQUE

Create 2 cm wide, superiorly based periosteal flaps with the lateral borders just barely overlapping the temporal crest (**Fig. 16A**). Dissection is easiest with a large Cottle dissector.

Periosteal flaps are also possible through upper lid incisions but lend to less accuracy, more difficulty in dissection, and less natural look for lack of wider undermining (**Fig. 16B**).

Incise the eyebrow at the junction of its mid- and lateral thirds, carefully angling the incision

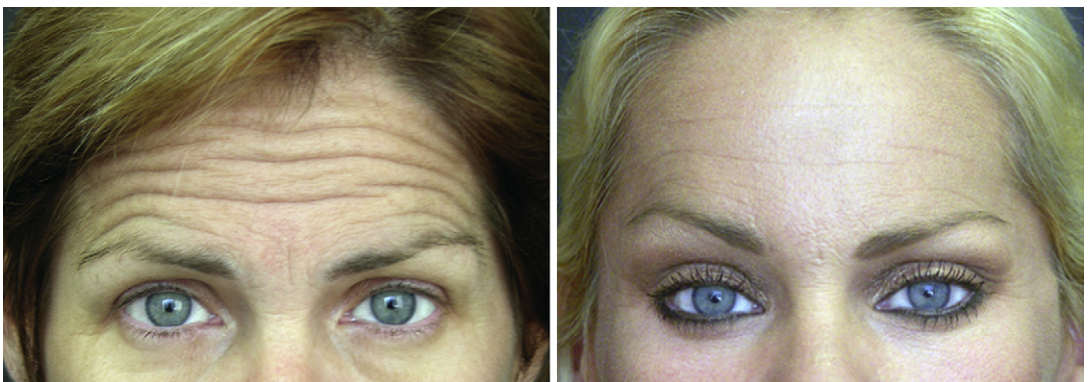

Fig. 15. 49-year-old woman shown before, and then 1 year after a coronal lift and corrugator resection, emphasizing the vertical and transverse line release that occurs when the lift is on top of, rather than beneath the periosteum.

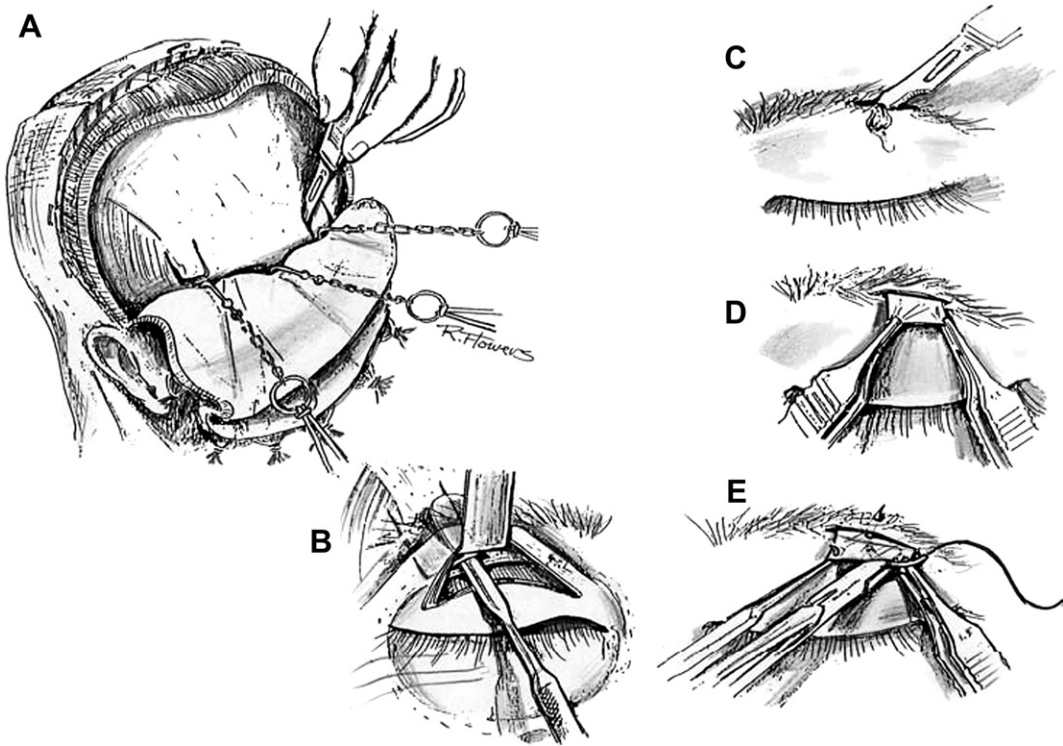


Fig. 16. Superiorly based periosteal flaps are extremely effective in people who have developmentally low brows (this includes most men but occasionally women). (A) Make the flaps 2 cm wide, and 2 to 3 cm long, with the lateral border extending to the temporal crest. (B) The flaps are possible through upper lid or brow incisions, but are much more difficult, and generally not as successful. (C) Make an incision at the junction of middle and lateral thirds of the brow, properly angling the incision to minimize injury to the hair follicles. Spread the incision with the blunt edge of small scissors. (D) Deliver the periosteal flap through the incision but delay its closure. (E) Place simple interrupted sutures through the brow and the periosteal flap. Delay ligating the sutures until after scalp tailoring and closure. Trim the periosteal flap so that it drops within the tissue as the brow is closed.

so that it parallels the hair shafts. When the incision is deep to the follicles, bevel incision cephalad, opening through to the deep side of the flap by blunt dissection with a spreading instrument (**Fig. 16C**).

Deliver the periosteal flap through the incision, but delay adjustment, trimming and suturing until

after scalp tailoring and closure (**Fig. 16D**). Suture the flap with simple interrupted sutures into the deep brow, trimming and discarding any redundant periosteal flap tissue (**Fig. 16E**).

This technique, used on one side only, is a tremendous aid in achieving symmetry, when one brow is significantly lower than the other.⁸

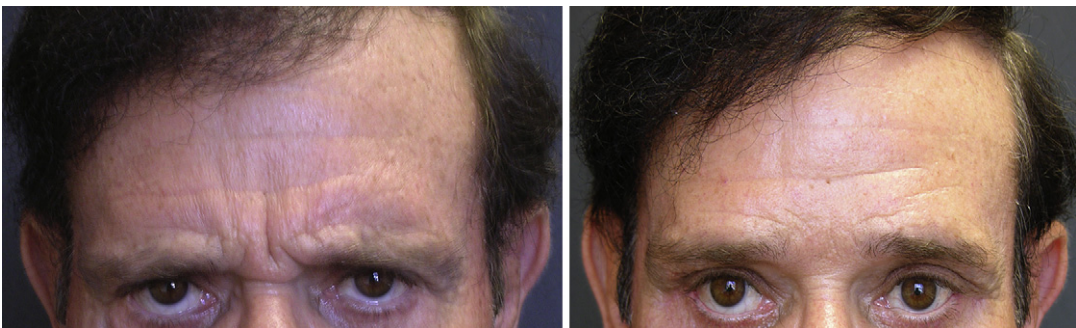


Fig. 17. Patients like this gentleman with low and asymmetrical eyebrows from birth benefit from periosteal flaps and other assisting maneuvers to secure long-term lateral brow elevation.

ADDING SECURITY TO THE LIFT BY GALEAL SUPPORT

Know from the beginning that it is very difficult to correct asymmetrical brows with extra pull on the more ptotic side, even when using the “five-to-one” rule, discussed later in this article. The difficulty often relates to asymmetrical development of the boney orbits, with one entire orbit being lower on one side. (The right brow and/or orbit is lower in 85 % of patients, the left lower in 7%, and the two brows essentially equal in the remaining 8%).¹²

The quest for more secure support and permanency to the lifted lateral brow, especially when dealing with the lower side in significant brow asymmetry, led the authors to refine the fixation of the brow by manipulation of the galeal tissue.

Removal of subgaleal areolar tissue (the superficial layer of the deep temporal fascia) in the temporo-parietal area helps considerably in long-term brow elevation, and is a consistent part of the authors’ coronal, and related other types of large forehead flap operations (Fig. 18). The exchange of filmy gliding tissue for scar fixation makes a difference. Leaving this gliding tissue centrally, however, allows the initially overelevated central brow to eventually drop back into a normal




Fig. 18. Removal of the gliding subgaleal areolar tissue, in the temporo-parietal secure long-term brow elevation laterally. Leave the tissue centrally to help self-correct the initial central elevation that comes from lateral lifting.

position, providing there are no large raw areas from central frontalis muscle or procerus resection, a common mistake by many practitioners.

Occasionally suturing the galea to a drill hole tunnel in the temporal crest (Fig. 19) also helps secure the brow fixation as. Tissue glue to secure the frontal flap, on the other hand, tends to convert the early and self-correcting central brow overelevation into a permanent deformity, with less effective permanency laterally. The authors avoid it in their practices.

TRANSVERSE FOREHEAD WRINKLE ELIMINATION

The frontalis muscle activates subconsciously to correct compromised forward vision caused by ptotic brows and/or pseudoblepharoptotic (or truly ptotic) upper lids. This activation causes transverse forehead lines or wrinkles (Fig. 20). The wrinkling, often absent in childhood and infancy, increases with progressive loss of baby fat (Fig. 21). Although frontalis muscle excision can eliminate some of these wrinkles, and possibly improve appearance in still photography, animation reveals bizarre forehead expressional movements,

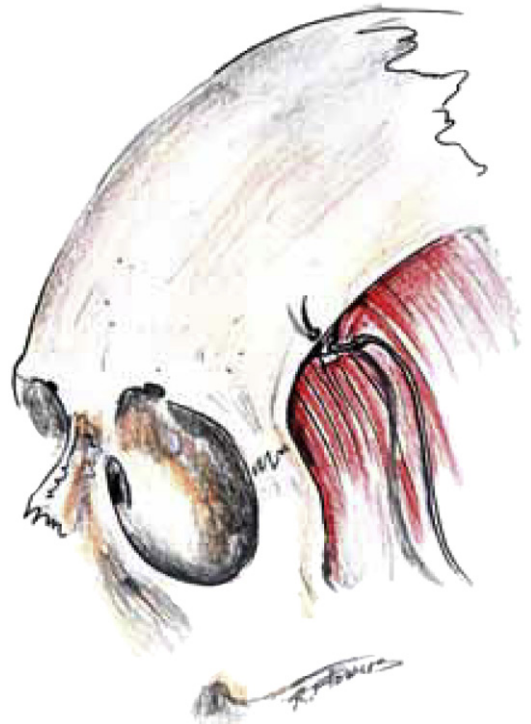

Fig. 19. A suture passed through a small bony tunnel at the temporal crest (made with two superficially angled drill holes) at the temporo crest provides an anchor to secure the galea of the frontal flap to the boney skull.

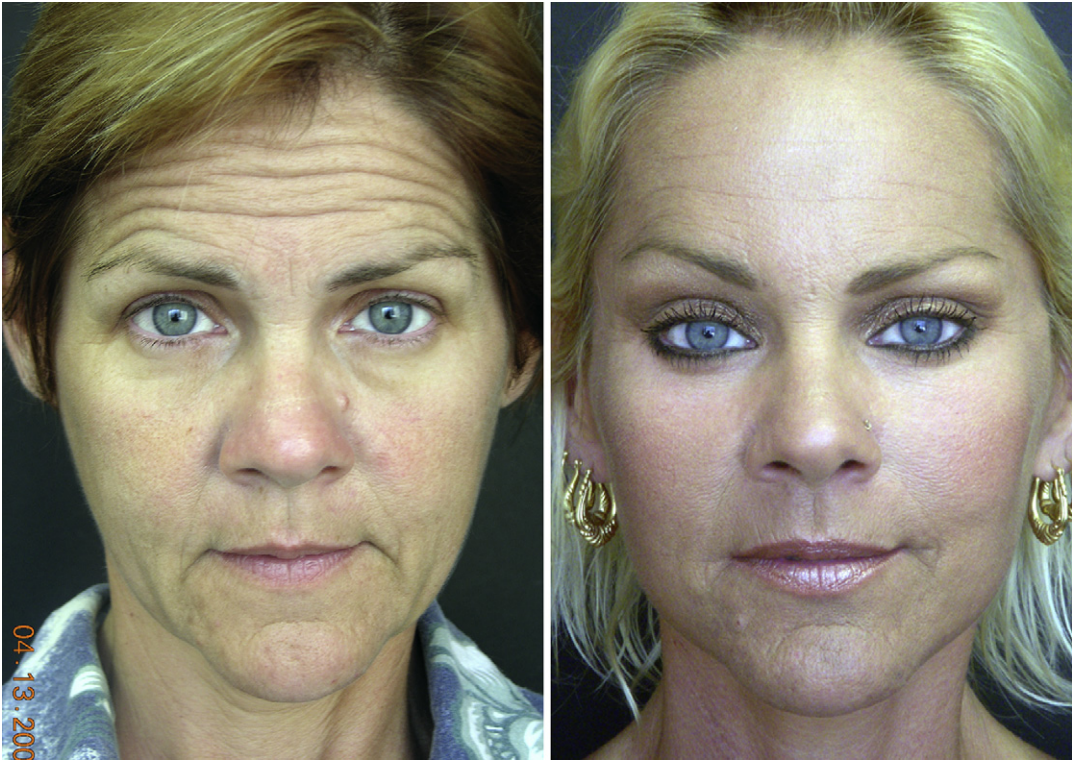

Fig. 20. 49-year-old woman with coronal lift and corrugator resection, with Mag 5 (midcheek lift, two-layered canthopexy, and lower lid blepharoplasty). No upper lid blepharoplasty was done. She may fall into the category of one requiring shortening of her forehead to totally eradicate the transverse wrinkling, which was so profoundly deep to start with.

with absent movement centrally (where excised), and compensatory exaggerated movement laterally (where muscle and nerve function were preserved). Botox is capable of causing similar forehead deformity.

One never should need to resect frontalis muscle for forehead wrinkle elimination.¹³ A well-done brow lift (with upper blepharoplasty when

indicated) (**Fig. 22**) eliminates transverse forehead wrinkling in 97% of all foreheads, although very deep creasing sometimes persists for months before fading. Rarely, the creasing is so severe, and the brow positioning so low, that transverse wrinkling never totally disappears. On the other hand, all that is needed to eradicate transverse wrinkling is an upper lid blepharoplasty. Most



Fig. 21. Four-year-old and 23-year old photo of same person showing the increased visibility of frontalis activity with the passage of years, most likely because of the atrophy of baby fat.

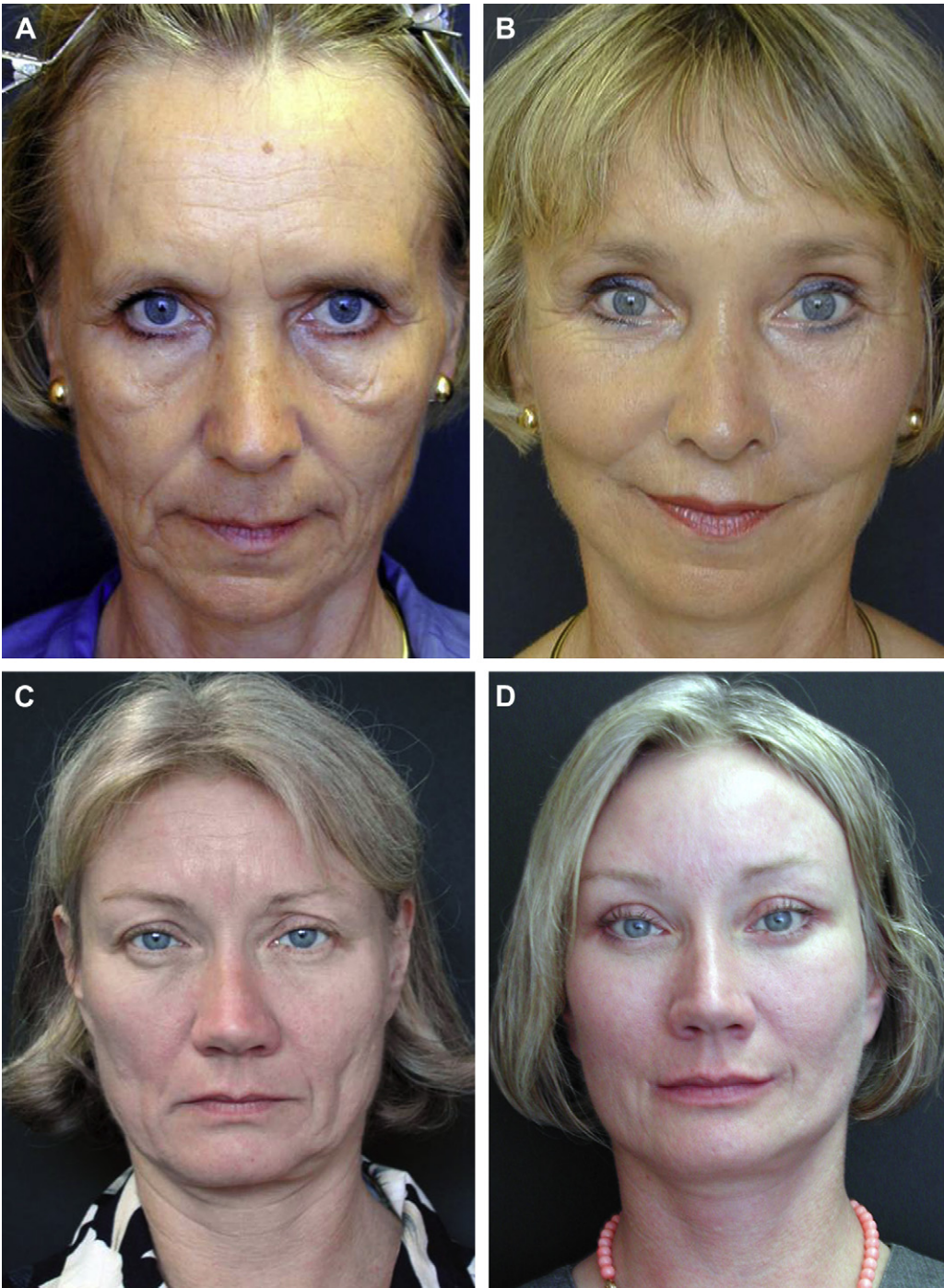

Fig. 22. (A, B) 54-year-old northern European woman with high forehead and marked brow ptosis, treated with coronal lift and corrugator resection. Note the disappearance of vertical frown lines and transverse frontalis lines by 1 year after surgery. No scalp was removed across the central 8 to 10 cm of the scalp, meaning there was insignificant elongation of the central brow. (Facelift and other midcheek procedures also accompanied) (C, D) A well-done brow lift with an upper blepharoplasty (when indicated) eliminates 97% of all transverse forehead creases, as it did in this woman, although it may take a year or more for them to fade away.

often this takes place in people from eastern Asia (Fig. 23), but it occasionally presents in other ethnicities. The cause is universally the same: severe lid overhang (pseudoblepharoptosis), commonly associated with poor lid fold invagination. Often there is an accompanying, but hidden, true lid ptosis. In these persons, the ptosis also must be corrected to alleviate the wrinkling. But most often a combination of brow and upper lid repair comprise the magic formula for transverse forehead crease eradication, not muscle excision.

SCALP RESECTION—HOW MUCH AND WHERE

The authors recommend a maximal lift at the temporo–parietal junction area and very little—if any—central scalp excision. When there is significant brow asymmetry (as there usually is), remove some central scalp on the more ptotic side to help achieve symmetry.¹⁴ Fig. 24 shows how lid and brow symmetry were improved and lovely lid folds created, just from coronal lift and corrugator resection. The patient’s eyelids were not touched. Of more importance is the authors’ guide for the amount of scalp resection laterally. It is the senior author’s “five-to-one” rule; for each 5 mm excised, expect approximately 1 mm of long-term elevation. This is because the posterior flap

moves forward and compromises the lateral lift’s effectiveness. But the main significance in the “five-to-one” rule comes in the correction of brow asymmetry, which responds to the following technique. Do a maximal scalp excision on the lower side, within the limits of a reasonably comfortable closure, maintaining good blood supply (for uncomplicated wound healing). For the scalp excisions, it is of utmost importance to have a good pair of D’Assumpcao assessing forceps (Fig. 25). If brow position is equal on both sides, do a slightly less-than-maximal excision (as described previously) on the first side. A maximal excision on the second side follows, which usually harvests a little less scalp than the first side.

The point of maximal excision should be at the parieto–temporal junction, on a line axis crossing the point where scalp hair is closest to the lateral brow. The amount of excision and the tension of closure diminish quickly as the incision moves centrally, and as it moves caudally. Always angle the scalpel parallel to the direction of hair growth when incising the scalp to prevent the injury to the hair follicles.

When there is asymmetry, decide how much more elevation is desirable both laterally, but also centrally on the more ptotic side. Once again, on the more ptotic side do a maximal excision. On

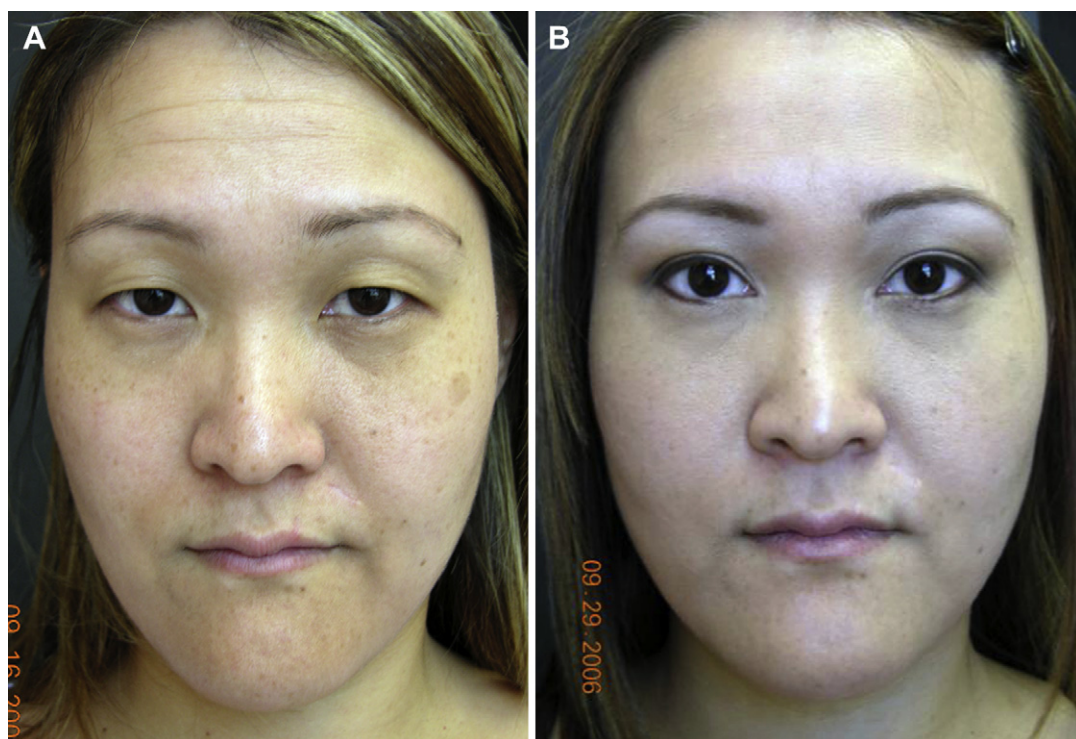

Fig. 23. (A) 32-year-old female with marked wrinkling of the forehead associated with heavy Asian eyelids. (B) Four months after Asian blepharoplasty with total elimination of forehead wrinkling well underway.

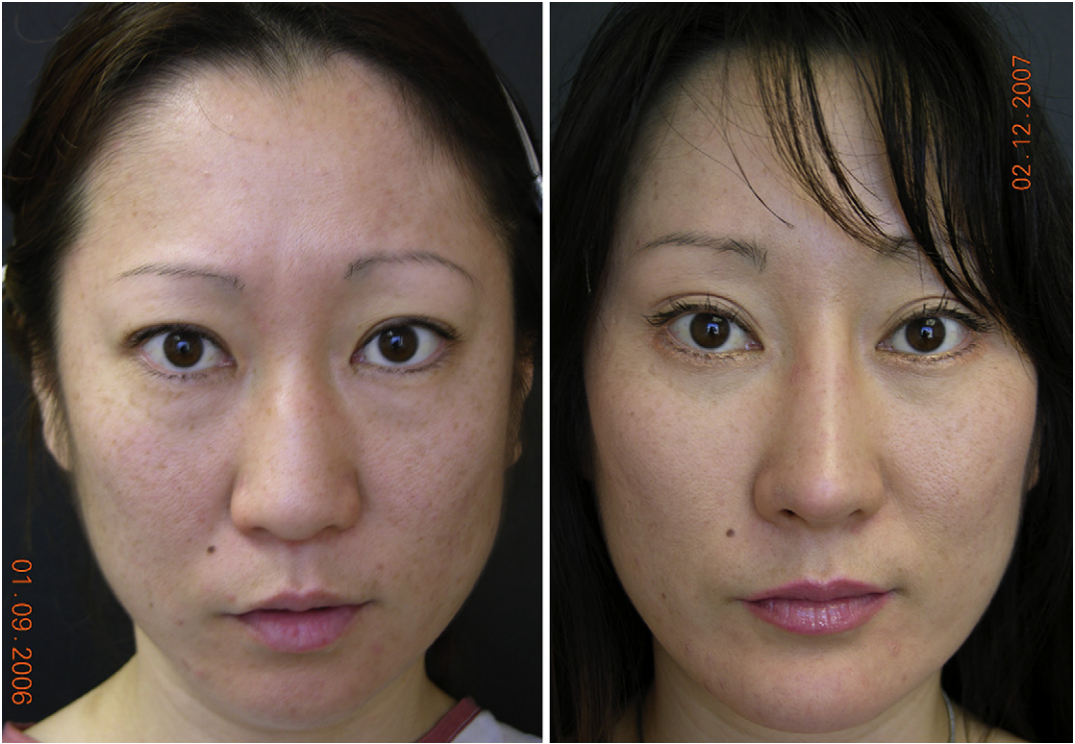


Fig. 24. 38-year-old East Asian woman, shown before coronal and corrugator resection surgery, and 1 year later. No upper eyelid surgery was done. Because of the differential scalp excisions, brow symmetry was improved, and beautiful lid folds emerged, simply from the brow elevation. The corrugator excision caused the visible frown in the forehead to totally disappear.

the less ptotic side, mark the scalp with the assessing forceps with the same maximal tension used on the more ptotic side, where the initial excision was made, but do not remove as much as the assessing forceps would indicate. Instead, reduce that second side excision by approximately five times the amount of desired differential

correction between the two sides. For instance, if a 2 mm height disparity exists in the two brows in their closed eye resting position preoperatively, back off, reducing the amount of excision suggested by the assessing forceps on that second side by (approximately) five times the 2 mm desired correction differential, equaling 10 mm.

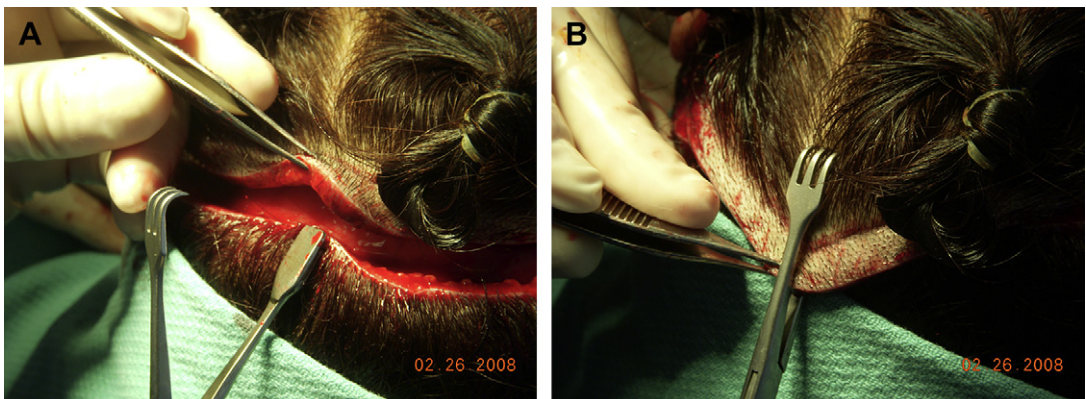


Fig. 25. (A, B) D'Assumpcao assessing (flap marking) forceps are invaluable in determining the appropriate amounts of tissue for removal. Make sure the forceps lies tangential to the scalp when assessing, or excessive tissue may be removed. (A) Securing the underside of the forceps into the posterior edge of the posterior flap. (B) Marking the amount of scalp tissue available for excision.

This (approximately) 10 mm must be subtracted from the already inevitably diminished amount of skin available for excision from the second side. This technique offers the best chance of correcting brow asymmetry by differential excision, but even it often disappoints, probably because of underlying orbital and facial asymmetry.

It is the authors' strong recommendation that surgeons incorporate one of the adjunctive methods (periosteal flaps or galea–periosteal suture anchored in temporal crest bone tunnel) when there is significant brow asymmetry. Endotine devices are another method of enhanced support, which the authors have elected not to embrace, because of its deforming nature, expense, and lack of meaningful follow-up.

Expect a lot of initial lift centrally from the lateral scalp lift alone, even without removing any tissue across the central 8 to 10 cm of the scalp. Remove only the medial scalp necessary to address the asymmetrically lower brow, and from the lower side only, except in the unusual situations where a major brow droop exists centrally on both sides. For correction of asymmetry, assume 1 mm of correction for each 2 mm excised medially on the asymmetrically low side, but total correction of significant asymmetries is unlikely. Diabolically shaped medial brows with profound medial ptosis (as sometimes results from lateral butterfly or other types of lateral emphasis excisions) may require significant medial excisions, but this deformity rarely occurs naturally.

Understanding the difficulty of getting the long-term lateral lift hoped for, and the incredible ease of overcorrecting centrally, is key to deciding the amount and location of scalp resection in a coronal brow lift. There is always help available from periosteal flaps and temporal crest drill holes (and sutures) if there is significant asymmetry to be corrected. Bone screws are an additional possibility, as is suturing the galea or even deep brow tissue to an elevated position on the lower forehead periosteum. There are also possibilities of suturing galea- or periosteum-containing frontal flaps to the temporalis fascia, and adding tissue glue for additional lateral support.

CORRECTING EYELID ASYMMETRY CAUSED BY ASYMMETRICAL BROW PTOSIS

When there is significant brow ptosis, lid skin beneath and attached to the brow, especially that above the supra tarsal fold, cascades over the crease, diminishing the quantity of the visualized pretarsal skin segment. When one brow is lower than the other, this skin overhang on that side creates a noticeable eyelid asymmetry, which far

exceeds any noticeable facial asymmetry resulting from simple brow asymmetry. This is of special significance when pseudoblepharoptosis (or lid overhang) obscures pretarsal skin visibility, which is especially common in, but not limited to, people from eastern Asia. Whatever a person's ethnicity, most, if not all of the lid asymmetry resulting from the brow asymmetry hides beneath the upper lid tissue overhang. If a person who has this condition undergoes either a symmetrical skin, or skin–muscle excision type blepharoplasty, or an invagination type blepharoplasty, the largely unnoticed brow asymmetry transforms into a much more significant eyelid asymmetry, which then becomes very noticeable (see **Fig. 23**). Whenever this pretarsal asymmetry exists as a somewhat visible, partially hidden or totally concealed phenomenon, it is likely to be exposed by upper lid excisions or invaginations, and requires additional or alternative correction for the brow induced upper lid asymmetry. This is not only important for a pleasing outcome, but essential if one expects patients to be pleased with their outcome. The authors suggest that surgeons use one or more of the following techniques to remedy the lid asymmetry¹⁵ (**Fig. 26**):

- Correcting asymmetry by doing a greater scalp excision on the more ptotic side laterally, and removing twice the millimeters of desired brow correction from the medial brow on the lower side

- Contriving additional brow support on the lower side with a superior-based periosteal flap or a temporal crest anchor suture, or other methods of enhanced unilateral support

- Removing more eyelid skin above the supratarsal crease on the side of the lower brow (see **Fig. 27** for a good technique to accurately assess the amount of skin for removal)

- Removing more supratarsal muscle (beneath the skin excision) on the lower brow side

- Designing a slightly taller pretarsal skin–muscle segment during blepharoplasty on the side with the lower brow, and securing it to a correspondingly higher point on the tarsus. This is applicable only when a lid invagination or Asian lid operation is performed, with or without a forehead lift.

CORRUGATOR MUSCLE EXCISION

Maximal corrugator excision, sparing the supratrochlear nerves that run within its bulk is appropriate in most patients, but remove only muscle, and none of its surrounding connective tissue and subcutaneous fat. This way there will be no

Making Eyelids Appear Symmetrical When Brows Are Asymmetrical

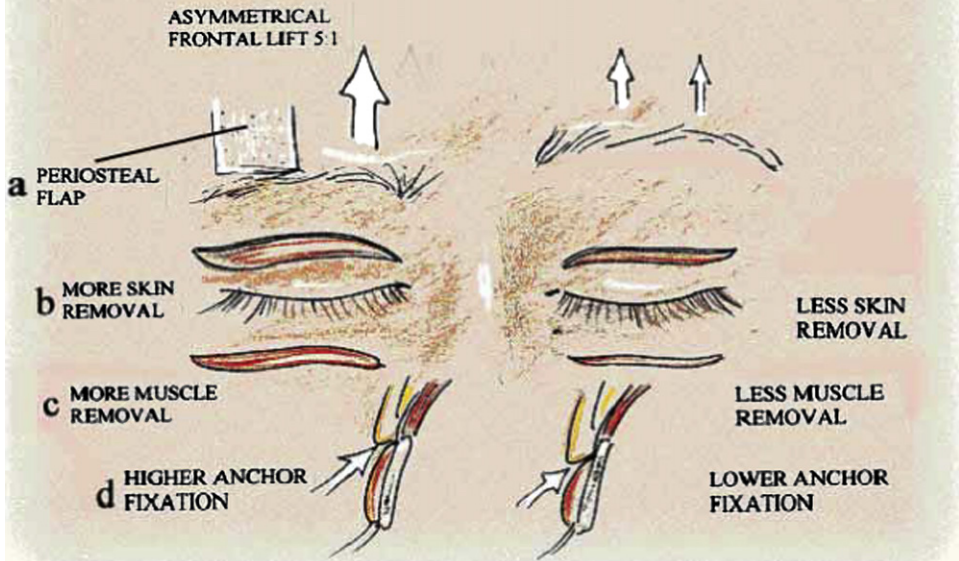


Fig. 26. (A-D) Illustration of the several different ways of creating symmetrical looking lids in the presence of asymmetrical brows. Do greater scalp excision on lower side, both medially and laterally, according to the guideline set out in the text, or create additional support by periosteal flaps into brows or by temporal crest bone anchored sutures into the galea of the frontal flaps. Removing more eyelid skin above the supratarsal crease on the side of the lower brow. Excising more muscle beneath the skin removed on the side of the lower brow. Designing a slightly taller pretarsal segment on the side with the lower brow.

depression in the area of muscle removal. Overactive and enlarged corrugator muscles often coexist with hypertrophy of their boney base of origin. The muscle prominences alone create the illusion of an angry or displeased disposition, as do the boney¹⁶ prominences. That fact, together with improved long-term outcome, gives ample reason to resect the muscle rather than transect, or score it. In, perhaps 1 of 12 operated patients, the authors use a very thin 1 cm wide osteotome (in preference to a burr) to chisel down those boney prominences at the muscles' glabellar origin. In the 200 plus times the authors have chosen this technique, there was no exposure of the frontal sinus mucosa. Anyone doing this operation nevertheless should exercise care in thinning this thickened bone.

Be aware that most people undergoing a frontal lift have some degree of compensated brow ptosis.¹ This means that this person constantly raises their brow in order to have comfortable and unobstructed forward vision. The frontalis muscle is in a constant state of contracture during waking hours. During its contracture, it acts as an antagonist to the corrugator muscle, its activation obscuring the prominence of the corrugator frown. This frown activity is likely to become more prominent when frontal or coronal lifting clears visual

obstruction, and allows the frontalis muscle to relax, and no longer counteract the corrugator activity. This effect can be anticipated by having the patient sit before the surgeon at the initial examination, close his or her eyes, and gently stroke his or her brow until complete forehead relaxation occurs. This maneuver provides powerful information—the true resting position of the eyebrows (the level to which the brows will drop after upper blepharoplasty removes overhanging, obstructing skin, and/or tissue) and what the frown muscles look like with frontalis relaxation—which inevitably occurs after a well-done coronal lift. The incredible energy conservation system of the human body kicks in and deactivates the frontalis.¹⁷

Most adults have prominent frowns on closing their eyes and relaxing their foreheads. This is why the corrugator muscle should be removed almost routinely when accessible by means of a coronal procedure, especially when a meaningful lift deactivating the frontalis muscle occurs. The low brow postures, the lid and brow overhang, and the prominent corrugator frown often go unnoticed by its host because of subconscious frontalis activation and head tilt that occurs every time a woman looks into a mirror, faces a camera, or is being scrutinized, especially by a plastic surgeon.

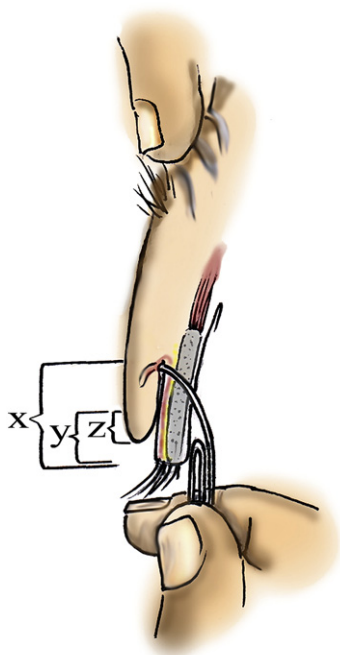


Fig. 27. Bend a slender metal paper clip so it can be slipped it underneath the lid overhang, approximating where the lid skin is folding, or where one would like it to fold (or be secured to the attached tarsus). If the brow is not to be elevated, then decide how much skin overhang (beyond the wire paper clip) is desirable. X represents the full height of the tarsus. Y is the amount of pretarsal skin one would like exposed, and Z is the amount the surgeon would like removed. Measure Z; multiply by two, and add an additional 1½ to 2 mm for going around the curve, and take out that amount. In many people, especially Asians, one will need to attach the pretarsal skin to an elevated position on the anterior tarsus.

Corrugator removal is optimal with direct visualization through an open approach, using 3.6 × (or greater) surgical loupes. This facilitates quick, accurate, and maximal removal, preserving both supratrochlear and supraorbital nerves.

Only when there are deep creases across the root of the nose should one remove the procerus muscle. Such removal is usually unnecessary for wrinkles alone, and only adds permanency to the early excessive (but usually temporary) medial brow elevation (as mentioned earlier) by creating a larger raw area encouraging fierce adhesion of the low central scalp flap to bone or periosteum.

FRONTAL LIFT CLOSURE

It is unnecessary to close the galea. Repairing the galea can transform a normally painless operation

into a very painful one. All patients experience tightness and pressure, but only two among the several thousand operated experienced pain. Those were the only two in whom the galea was repaired. The scars both of these ladies were no better than average when compared to the others having simple wide staple closure. Sutures placed in the scalp, especially when close together, promote areas of hair loss, often corresponding to each suture. Skin staples do not cause hair loss themselves, and will do so only in the case of excessively tight, ischemia-inducing closures. Such tight closures, especially when combined with excessive numbers of staples, are prone to create hair loss. There is no need for coronal patients to ever experience hair loss, or scalp loss, from overexuberant closure.

It is important not to overdo the hemostasis during the scalp closure, because cautery will cause irreversible hair follicle damage, causing postoperative alopecia. It is best to use the bipolar cautery inferior to the hair follicles, to minimize the hair loss. Removing the Rainey clips with special clip removers, not by pulling off the scalp, will minimize the bleeding during closure further.

Drain any residual blood underneath the scalp flaps prior to applying the final staples; then apply Barton-type pressure head bandage, and keep the patient's head elevated during the recovery period. Remove this pressure dressing the next day, and have the patient's hair shampooed before applying a light dressing. Remove the staples between 7 and 10 days.

OPEN LARGE FLAP/FRONTAL LIFT VERSUS ENDOSCOPIC LIFT

Why do an open frontal lift instead of endoscopic or other limited access procedure? Just as open large flap frontal lifts had begun to capture the hearts and minds of plastic surgeons, the endoscopic brow lift appeared on the scene. Its "high-tech" imagery and the desire to avoid a large procedure, as the frontal lift was often considered, lured many would-be open frontal lifters into the ranks of endoscopy. As years have passed, endoscopy seems to become a permanent addition to plastic surgery. The quest for excellence in outcome, however, keeps driving more and more surgeons back toward the open procedure with maximal corrugator removal, utilizing its generous access to make many other corrections.

If endoscopy worked as well as the open procedure, its desirability would be quite obvious: smaller incisions, less surgical time, and less visible scars and less morbidity.

Flip that coin over to the other side, and one could also ask why one might prefer the open frontal lift? There are a number of reasons:

A well-done open frontal lift with corrugator resection is the single most rejuvenating operation in plastic surgery, especially when combined with an enhanced cantho-pexy and midcheek lift.

The open frontal lift generally facilitates a more effective and permanent lateral lift than does endoscopic brow lifting, (which tends to overcorrect centrally and under-correct laterally).

The open technique allows a quick, simple, and comprehensive corrugator muscle removal, which, in the authors' experience permanently eliminates the corrugator frown, and does so without causing any depressions or dimples. Good corrugator removal is certainly possible with endoscopy, but to do a thorough removal through the endoscope takes such an exceptionally long period of time that few surgeons are willing to do it.

In people who have profound asymmetry and developmentally low eyebrows, the open approach lends itself to the use of the periosteal flaps as suspenders that secure one or two brows permanently into their desired location.

Of immense importance is the fact that the open technique facilitates an optimal cantho-pexy-midcheek lift that is secure and lasts indefinitely.

Direct visualization and orientation minimize the chance of injuring any of the sensory nerve branches, as well as any motor branches of the facial nerve. (Even during learning curves, such complications are not acceptable.)

The open approach allows modification of prominences of the bony orbital rims,¹⁸ expansion of the orbits, removal of bony prominences at the origin of the corrugator muscles (which contribute to an angry look), contouring of frontal bossing, removal and treatment of other such abnormalities as osteoma, and other options such as bone contouring with implants or methyl methacrylate.

To summarize, the open approach facilitates an optimal facial repair, along with many adjunctive procedures, which are difficult if not impossible through endoscopic approaches. There is no question that endoscopes help, but to claim the

best results one possibly can deliver, one might want to adopt the open approach.¹⁹

WHERE DOES THIS LEAVE ISOLATED UPPER BLEPHAROPLASTY?

After reading this article, the question arises "Are there any situations where isolated upper blepharoplasty is indicated?" The answer is "yes." There are three:

1. The patient whose pseudoblepharoptosis is so great that even maximal brow elevation fails to clear the visual fields. Upper lid excisions will return that function to the frontalis muscle.
2. People who have no significant compensated brow ptosis, and whose resting eyebrows are in a reasonably good position (this is quite unusual).
3. Young people from eastern Asia whose brows are excessively elevated in order to allow unobstructed vision. The profound drop in brow position from an invagination (or double)-type upper blepharoplasty can improve the appearance of these young people markedly.

SUMMARY

It is appropriate that lifts in facial rejuvenation begin at the top. To lift any part without first making sure the area superior to it is in a proper position is foolish, for it inevitably results in a traffic jam of unattractive crowded tissues at the zone where the lifted encounters the unlifted. This commonly occurs in the zone where the lateral orbital region (eyelids and brow) joins with the temple. That is why a lateral emphasis (preferably open) frontal lift deserves to be a regular part of a surgeon's prescription. A well-done coronal lift not only produces awesome results in and of itself, it also provides optimal access for the best possible, and longest-lasting, midcheek lift, corrugator frown removal, and even optimal lower lid blepharoplasty and cantho-pexy.

REFERENCES

1. Flowers RS, Duval C. Blepharoplasty and peri-orbital surgery. In: Aston SJ, Beasley RW, Thorne CHM, editors. *Grabb and Smith's plastic surgery*. 5th edition. Philadelphia: Lippincott-Raven Publisher; 1997. p. 612.
2. Flowers RS, Nassif JM. Aesthetic periorbital surgery. In: Mathes SJ, editor. *Plastic surgery*, vol. 2. 2nd edition. Philadelphia: Saunders Elsevier; 2006. p. 86-7.
3. Flowers RS. Cosmetic blepharoplasty: state of the art. In: Habal MB, editor. *Advances in plastic and*

- reconstructive surgery, vol. 8. St. Louis (MO): Mosby Yearbook; 1992. p. 34–5.
4. Flowers RS. Cantho optimaplasty. Instructional courses DVD. Baltimore (MD): ASPS; 2007. (ASPS Lecture).
 5. Flowers RS. Mag 5: cantho optimaplasty. Instructional course DVD at ASAPS. New York 2007.
 6. Flowers RS. The art of eyelid and orbital aesthetics. *Clin Plast Surg* 1987;14:709.
 7. Flowers RS. Blepharoplasty and coronal lift. Teleplast symposium video, Plastic Surgery Educational Foundation audio-visual library. 1987 and forward.
 8. Flowers RS, Caputy GG, Flowers SS. The biomechanics of brow and frontalis function and its effect on blepharoplasty. *Clin Plast Surg* 1993;20:256.
 9. Flowers RS. Corono–canthopexy: our most rejuvenating operation (and associated procedures). Instructional course, ASPS Annual Meeting, October 2003, RSF handout.
 10. Flowers RS. Periorbital aesthetic surgery for men: eyelids and related structures. *Clin Plast Surg* 1991;18:706.
 11. Flowers RS. Blepharoplasty in the male. In: Courtiss E, editor. *Male aesthetic surgery*. St Louis (MO): CV Mosby; 1981. p. 703.
 12. Flowers RS. Complications after blepharoplasty—analysis. In: Goldwyn RM, editor. 2nd edition, *The unfavorable result in plastic surgery, avoidance, and treatment*. vol. 2. Boston: Little, Brown and Co; 1984. p. 508.
 13. Flowers RS. Simplified principles of the best operation in aesthetic surgery: the well-done frontal lift. Lecture and Panel Discussions at ISAPS Congress in Yokohama. Japan, April 16–21, 1995.
 14. Flowers RS, Flowers SS. Precision planning in blepharoplasty: the importance of preoperative mapping. *Clin Plast Surg* 1993;20:303.
 15. Flowers RS. Brow asymmetry, its treatment, and its effect on blepharoplasty. Presented at the annual meeting of AAPS. Scottsdale (AZ): 1980.
 16. Flowers RS. Advanced blepharoplasty principles of precision. In: Gonzales-UI-loa M, Meyer R, Smith JW, editors, *Aesthetic plastic surgery*, vol. 2. Padova (Veneto): Piccin Press; 1987. p. 115.
 17. Flowers RS. The open approach to forehead and brow lifting. *Aesthetic Surgery Journal* 1998.
 18. Flowers RS. Orbital rim contouring. In: Ousterhaut D, editor. *Aesthetic contouring of the craniofacial skeleton*. Boston: Little, Brown and Co.; 1991. p. 243–56.
 19. Flowers RS. Colloquium. *Ann Plast Surg* 1978;1:66–9.