

Letters to the Editor

To the Editor:

In your Editorial Tribute to Karl Zucker mention was made of him visiting United States, Europe, Asia and South America (1).

In February 1990, Karl Zucker visited our combined Gastrointestinal Clinic at Groote Schuur Hospital in Cape Town, South Africa to receive training in endoscopic retrograde cholangio-pancreatogram (ERCP). In his modest way, he mentioned that he had done a few laparoscopic cholecystectomies before leaving for Africa. He fired our interest and showed us how to do this operation on 2 pigs with instruments scrounged from the gynaecologists. As a result of his encouragement the first laparoscopic cholecystectomy was done in South Africa (and possibly in Africa) in October that year. We can therefore with justification add Africa to the continents in which he provided the spark that lit the laparoscopic explosion.

Lala Kahle, Karl.

Sydney Cullis FCS, FRCS
Philip Bornman FRCS, FCS, MMed
*Department of Surgery
Groote Schuur Hospital
University of Cape Town
South Africa*

REFERENCE

1. *Surg Laparosc Endosc Percutan Tech* 2002;12:3:199.

Retained fecalith: Laparoscopic removal

To the Editor:

Smith et al. should be credited with describing the first case of retained fecalith after laparoscopic appendectomy treated successfully by relaparoscopy (1). They rightly pointed out that there had been only one prior case report on retained fecalith, but which was treated by open surgical drainage (2). Indeed, other than the difference in surgical access, the two cases are rather similar. Intriguingly, we have just encountered a case of retained fecalith that differs from the aforementioned cases in some important clinical aspects.

The patient was a 22-year-old man who underwent an emergency laparoscopic appendectomy for phlegmonous

unperforated appendicitis. The operation was uneventful except for the inadvertent tearing of the appendix specimen by the endograsper during forceful extraction through the umbilical cannula. The operating field was swabbed thoroughly afterward. On the fifth postoperative day, because of persistent fever, leukocytosis, and diarrhea, computed tomography (CT) was performed and disclosed loculi of fluid amid dilated bowel loops in the right lower quadrant where a dense opacity was also noted (Fig. 1A). Relaparoscopy via the previous portals found a 1 × 0.5-cm fecalith inside one of the fluid loculi. It was removed along with the drainage of all turbid fluid collections. The fever subsided rapidly, and the patient made a swift recovery. Repeat noncontrast CT confirmed complete clearance of the opacity (Fig. 1B).

The two previously published cases closely resembled each other. First, they both had subhepatic abscesses related to a missed fecalith in the subhepatic space at presentation. Second, the appendix was perforated at operation, spontaneously in one case and due to difficult dissection in the other. Plausibly, the fecalith had been extruded through the perforation. Third, in both cases, subsequent to the removal of the appendix, vigorous irrigation had been carried out in the presence of localized soiling or abscess. There is a possibility that the fecalith was washed to the subhepatic space during irrigation, particularly if the latter had been conducted with the patient in the Trendelenburg position. Notably, fecaliths can slip under the liver and evade detection even with the use of a 30° scope and lavage, as is the case with missed spilled gallstones at laparoscopic cholecystectomy (3). Fourth, the two patients experienced recurrences of subhepatic collections despite repeated drainage; hence, their post-appendectomy courses were protracted, being 7 weeks and 5 months, respectively.

In contrast, our patient had fluid collections close to the original operation site as a consequence of dropped fecalith during retrieval of the fragmented specimen. One course of laparoscopic drainage and fecalith removal was met with complete success. Most importantly, we refrained from using irrigation in this patient, as we routinely do for all patients with localized perforation and contained abscess around the appendix (4). Conceivably, contaminated lavage fluid—and fecaliths—may be spilled over virtually every crevice of the peritoneal cavity, defying complete removal by suctioning. As a result,

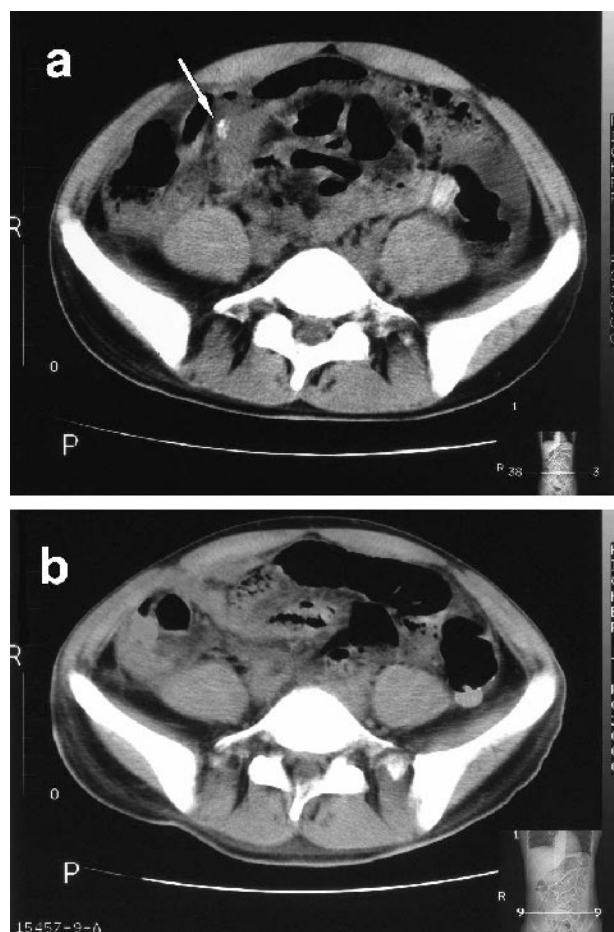


FIG. 1. **a.** Abdominal CT scan showing fluid collection in the right lower quadrant containing an opaque fecalith (arrow). **b.** Repeat CT scan showing absence of the opacity the next day following relaparoscopy to remove the fecalith.

abscesses may form in remote sites, some of which can be unusual or unexpected. Of note in this regard is the recent report of an apparently puzzling case of a man in whom a 'left' scrotal abscess developed on the second day following laparoscopic appendectomy for localized perforated appendicitis (5). In short, it would seem more prudent to use gauze swabs introduced through a reducing sheath to mop clean the right lower quadrant (6)—a time-honored technique used in open appendectomy that has been shown, albeit arguably, in several studies to have less risk of intraabdominal abscess formation as compared with its laparoscopic counterpart (1).

W. T. Ng
J. Chan
N. Fan
M. Y. Leung

Department of Surgery (WTN, JC, NF)
Department of Radiology (MYL)
Yan Chai Hospital
Tsuen Wan
Hong Kong

REFERENCES

1. Smith AG, Ripepi A, Stahfeldt KR. Retained fecalith: laparoscopic removal. *Surg Lap Endosc* 2002;12:441–442.
2. Strathern DW, Jones BT. Retained fecalith after laparoscopic appendectomy. *Surg Endosc* 1999;13:28–299.
3. Ng WT. Development and standardization of a most cost-effective laparoscopic appendectomy technique in a community hospital with best ergonomics and cosmesis. The Hospital Authority Convention, May 4–6, Hong Kong.
4. Ng WT, Lee WM. Remediating some complications of laparoscopic cholecystectomy. *Surg Lap Endosc* 1998;8:160.
5. Kollias J, Gallery RM. Left scrotal abscess complicating laparoscopic appendectomy. *Aust N Z J Surg* 1996;66:568–569.
6. Ng WT, Lau HW. Left scrotal abscess complicating laparoscopic appendectomy: comment. *Aust N Z J Surg* 1998;68:152–153.

Response to Dr. Ng et al.

To the Editor:

We would like to thank Dr. Ng for sharing his significant experience in laparoscopic appendectomy and his insightful commentary. As demonstrated by both case reports, complications associated with retained fecaliths following appendectomy are becoming more prevalent with the increased use of the laparoscopic technique, similar to the increase in common bile duct injuries following the introduction of laparoscopic cholecystectomy. Regardless of the sterilization method used at the initial surgery, leaving a contaminated foreign body in the peritoneal space may lead to abscess formation.

Following removal of the diseased appendix, treatment of the infected right lower quadrant at the initial surgery is controversial. In 1926, Kirschner's (1) review of 1626 patients with peritonitis, the vast majority due to appendicitis, compared intraoperative lavage to mechanical cleansing and noted no difference in mortality rates. Peritoneal lavage, dilution being the solution to pollution and first used by Price in 1905, reduces the colony count within the peritoneal cavity, theoretically reducing infectious complications. However, large volumes of irrigant (25–30 L) (2,3) are required to reduce the subsequent rate of abscess or wound infection. Addition of metronidazole (4), terodiline (5), chlorhexidine-gluconate (6), or gentamicin (7) to the lavage fluid is ineffective and may result in complications such as sclerosing encapsulating peritonitis (8).

Theoretic objections to peritoneal lavage include dissemination of the bacteria (a belief first expressed by Deaver in 1910) (9), reducing the concentration of opsonins in contact with the bacteria, and the reduced abil-

ity of neutrophils to reach the bacteria (white cells cannot swim) (10). Downsides to mechanical cleansing using gauze swabs are the inability to completely remove the inoculum and the inability to affect bacterial spread via the intraperitoneal circulation.

The laparoscopic approach to appendicitis reduces the incidence of postoperative wound infection. Other than systemic antibiotics and meticulous surgical technique, no proven method further reduces postoperative infectious complications. Most studies lack adequate controls, involve too many uncontrollable variables, or have too few patients to recommend one method over the other. Irrigation may treat the physician more than the patient and may disseminate both bacteria and the fecalith. If irrigation is chosen, the surgeon must completely remove all remaining fluid prior to completing the case. However, no method can sterilize a contaminated foreign body, the retained fecalith.

Kurt Stahlfeld, MD, FACS
Department of Surgery
The Mercy Hospital of Pittsburgh
Pittsburgh, Pennsylvania

REFERENCES

1. Kirschner M. Die Behandlung der akuten eitrigen freien Bauchfellentzündung. *Arch Klin Chir* 1926;142:253.
2. Sugimoto K, Hirata M, Kikuno T, et al. Large-volume intraoperative peritoneal lavage with an assistant device for treatment of peritonitis caused by blunt traumatic rupture of the small bowel. *J Trauma* 1995;39:689-92.
3. Sugimoto K, Hirata M, Takishima T, et al. Mechanically assisted intraoperative peritoneal lavage for generalized peritonitis as a result of perforation of the upper part of the gastrointestinal tract. *J Am Coll Surg* 1994;179:443-8.
4. Saha SK. Efficacy of metronidazole lavage in treatment of intra-peritoneal sepsis. A prospective study. *Dig Dis Sci* 1996;41:1313-8.
5. Rosman C, Westerveld GJ, Kooi K, Bleichrodt RP. Local treatment of generalised peritonitis in rats; effects on bacteria, endotoxin and mortality. *Eur J Surg* 1999;165:1072-9.
6. Vallance S, Waldron R. Antiseptic vs. saline lavage in purulent and faecal peritonitis. *J Hosp Infect Mer* 1985;6(Suppl A):87-91.
7. Lally KP, Shorr LD, Nichols RL. Aminoglycoside peritoneal lavage: lack of efficacy in experimental fecal peritonitis. *J Pediatr Surg* 1985;20:541-2.
8. Keating JP, Neill M, Hill GL. Sclerosing encapsulating peritonitis after intraperitoneal use of povidone iodine. *Aust N Z J Surg* 1997;67:742-4.
9. Hunt JL. Generalized peritonitis. To irrigate or not to irrigate the abdominal cavity. *Arch Surg* 1982;117:209-12.
10. Farthmann EH, Schoffel U. Principles and limitations of operative management of intraabdominal infections. *World J Surg* 1990;14:210-7.

Severe and persistent hypoglycemia: a life-threatening adverse reaction of intravasation of hyperosmolal contrast media

Key Words: Hypoglycemia, contrast agent, hyperosmolal

To the Editor:

We would like to share a clinical experience that we encountered about a life-threatening adverse reaction of intravasation of hyperosmolal contrast media during a retrograde cystogram, which may be particularly useful for surgeons, urologists, and radiologists.

A 58-year-old male patient with abdominal wall cellulitis and two draining sinuses, which appeared to be draining urine, was scheduled for retrograde cystogram for the evaluation of the suspected vesicocutaneous fistula. A hyperosmolal contrast media (diatrizoate meglumine, a fully saturated, ionic, monomeric, triiodinated benzoic acid derivative) was used for the procedure, which was seen to intravasate (escape of contrast media into the vascular system) during the injection, possibly due to trauma during the insertion of the Foley catheter. The procedure was immediately stopped, but a few minutes later the patient started to have generalized seizure activity. The serum glucose level was checked immediately and 50 ml of 50% dextrose solution (D50) was given intravenously in response to a serum glucose level of 10 mg/dL. An intravenous infusion of 5% dextrose solution (D5) was initiated. Repeated serum glucose levels remained below 60 mg/dL despite the 5% dextrose infusion, and intravenous injection of an additional 25 gm of dextrose solution was necessary every half hour for the next 24 hours to maintain a serum glucose level of approximately 70 mg/dL. There was no further seizure activity and the serum glucose level normalized after 24 hours.

Osmolality, viscosity, the site and speed of administration, and the chemical properties of a contrast agent are the main determinants of the type and severity of an adverse reaction [1]. Hyperosmolality is responsible in many hemodynamic side effects of contrast media [2], while inflammatory mechanisms appear to play an important role in systemic adverse reactions [3]. The intravasation of a hyperosmolal contrast agent may be fatal depending on the amount, speed of intravasation, the site, timing of resuscitation, the age, and general health of the patient [4-6]. Clinicians and radiologists should be aware and prepared to treat potentially fatal complications of hyperosmolal contrast media. Although intravasation of the hyperosmolal contrast media causing systemic adverse effects, including fatalities has previously been described (see references), hypoglycemic effect has

never been described before to our knowledge. Hypoglycemia may be one of these life-threatening complications, and any patient having symptoms of hypoglycemia and/or convulsions should be immediately treated with intravenous administration of concentrated glucose solutions without waiting for the laboratory results.

Newer hyposmolar contrast media should be preferred in most circumstances if possible during radiological studies and interventions, and it should be a must if intravasation is expected.

REFERENCES

1. Swanson DP, Dick TJ, Simms SM, Thrall JH (1985). Product selection criteria for intravascular ionic contrast media. *Clin Pharm.* 4: 527-538.
2. Spataro RF (1984). Newer contrast agents for urography. *Radiol Clin North Am* 22: 365-380.
3. Kozlowski C, Kollef MH (1992). Noncardiogenic pulmonary edema associated with intravenous radiocontrast administration. *Chest.* 102: 620-621.
4. Cove JKJ, Snyder RN (1974). Fatal barium intravasation during barium enema. *Radiology.* 112: 9-10.
5. Wheatley MJ, Eckhauser FE (1991). Portal venous barium intravasation complicating barium enema examination. *Surgery.* 109: 788-791.
6. Williams SM, Harned RK (1991). Recognition and prevention of barium enema complications. *Curr Probl Diagn Radiol.* 20: 123-151.

Adil Ceydeli, MD, MS
James Rucinski, MD, FACS
Department of Surgery
New York Methodist Hospital and
Weill Medical College of Cornell University
Brooklyn, NY 11215, USA